

PRELIMINARY REPORT

Multidisciplinary Investigation of Harbor Porpoises (*Phocoena phocoena*) Stranded in Washington State from 2 May – 2 June 2003 Coinciding with the Mid-Range Sonar Exercises of the *USS SHOUP*

February 2004

Scientific Investigation Team Members:

Stephanie Norman, NOAA Fisheries, Northwest Region

Bill McLellan, University of North Carolina, Wilmington

Ann Pabst, University of North Carolina, Wilmington

Darlene Ketten, Biology Department, Woods Hole Oceanographic Institute

Stephen Raverty, Ministry of Agriculture Food and Fisheries

Michelle Fleetwood, Armed Forces Institute of Pathology

Joseph K. Gaydos, SeaDoc Society, UC Davis Wildlife Health Center

Steve Jeffries, Washington Department of Fish and Wildlife

Tara Cox, Marine Mammal Commission

Brad Hanson, NOAA Fisheries, Northwest Fisheries Science Center

Brent Norberg, NOAA Fisheries, Northwest Region

Lynne Barre, NOAA Fisheries, Northwest Region

Dyanna Lambourn, Washington Department of Fish and Wildlife

Scott Cramer, Biology Department, Woods Hole Oceanographic Institute

Abstract

During the period of May 2, 2003 to June 2, 2003, the National Marine Fisheries Service (NOAA Fisheries) Northwest Marine Mammal Stranding Network received reports of 14 stranded harbor porpoise in Washington, an abnormally high number when compared to the average stranding rate of 6 per year recorded over the past decade. The reports coincided with use of mid-range sonar by the naval vessel *USS SHOUP* in Haro Strait between Vancouver Island (Canada) and San Juan Island (US) on 5 May 2003 and observations by researchers and the public who reported altered behavior of marine mammals in the area. Eleven porpoise were collected for necropsy.

NOAA Fisheries assembled a multidisciplinary team of biologists, veterinarians, veterinary pathologists, research scientists and a neuroanatomist who conducted extensive classical forensic necropsy examinations from 22 July through 24 July, followed by laboratory diagnostic and histological analyses and complemented by high resolution computerized tomography (CT) scans. Samples were taken for a variety of analyses including disease screening, parasitology, chemical contaminant and lipid analyses, aging studies, prey identification and domoic acid analysis. This report presents a summary of historical porpoise stranding reports, information on the discovery and collection of porpoise during the May to June timeframe, gross and microscopic findings from the necropsy examinations, analysis of the CT image data, and discussion on causes of mortality.

Over 70 percent of the specimens were in moderate to advanced states of decomposition which made interpretation of the cause of death difficult. The cause of death was determined for 5 of the 11 porpoises examined by the multidisciplinary team. Of these five animals, two were found to have suffered blunt force trauma, while illness (peritonitis, salmonellosis, pneumonia) was implicated in the remaining three cases. No cause of death could be determined for the remaining six animals. The examinations did not reveal definitive signs of acoustic trauma in any of the porpoises examined. The possibility of acoustic trauma as a contributory factor in the mortality of any of the porpoises could not be ruled out. The multidisciplinary team noted that lesions consistent with acoustic trauma can be difficult to interpret or obscured, especially in animals in advanced post mortem decomposition.

TABLE OF CONTENTS

Abstract	2
Introduction	4
Background	5
Materials and Methods	6
Results	8
Summary of post mortem examinations and laboratory results	49
Discussion	53
Conclusion	55
Literature Cited	56
Glossary	59

FIGURES

Figure 1. Reported porpoise strandings in Washington State 2 May – 2 June 2003

TABLES

- Table 1.** Reported harbor porpoise strandings in Washington State – 2 May-2 June 2003
- Table 2.** Spatial distribution of harbor porpoise stranding events in Washington State-1992-2003.
- Table 3.** Harbor porpoise stranding events in Washington State – 1992-2003 (April-June).
- Table 4.** Freezer types and specifications used to store and transport harbor porpoises prior to necropsy.
- Table 5.** Body composition of harbor porpoises examined during the necropsy session.
- Table 6.** Bacteriology results for harbor porpoise specimens.
- Table 7.** Trace mineral and vitamin A analyses of liver, kidney and vitreous humor.
- Table 8.** Summary of CT scan analyses.
- Table 9.** Summary of organochlorine concentrations in the blubber of stranded harbor porpoises.

APPENDICES

- Appendix A.** Sample Level A stranding form and completed forms for this investigation.
- Appendix B.** Phocoenid strandings in British Columbia, Canada (April-May 2003).
- Appendix C.** Porpoise investigation team members.
- Appendix D.** List of harbor porpoise stranding events in Washington State 1992-2002.
- Appendix E.** Marine mammal stranding events in Washington State (1 April – 30 June 2003).
- Appendix F.** Summary of post mortem findings in harbor porpoise stranded in Washington State 2 May – 2 June 2003.

INTRODUCTION

During the one-month period from 2 May – 2 June 2003, the Northwest Marine Mammal Stranding Network (Network) received reports of 14 harbor porpoises (*Phocoena phocoena*) dead on the beach, or floating, along the outer coast, in the Strait of Juan de Fuca, and in the vicinity of Whidbey Island and San Juan Island, Washington State (Figure 1; Table 1). This number represented a greater number of harbor porpoise strandings than noted in past years (Table 2). Of the 14 harbor porpoises, 12 animals stranded in inland waters (*i.e.*, the Pacific entrance to the Strait of Juan de Fuca through Puget Sound and the Southern Straits of Georgia south of the U.S./Canada border) and two along the outer Pacific coast (Table 1). Basic information (level A data) was collected from all 14 strandings, and specimen parts (whole bodies or heads) were collected from 11 of the stranded harbor porpoises (see Appendix A for sample Level A stranding form and completed forms for the animals in this investigation). The materials were frozen for later detailed examination and curation. In addition to the 14 harbor porpoises, one dead Dall's porpoise (*Phocoenoides dalli*) washed ashore briefly on May 14 then was swept away by the tide (see Figure 1, 03NWR05035 for location of Dall's stranding). Porpoises of both species were recovered in Canadian waters during the months of April and May (Appendix B); however, these animals are not included in this report.

Researchers and private citizens reported behavioral changes in whales and porpoises during military activities involving the naval vessel *USS SHOUP* transiting Haro Strait between Vancouver Island (Canada) and San Juan Island (US) on 5 May 2003. Specifically, witnesses reported seeing avoidance behaviors by a pod of Southern Resident killer whales (*Orcinus orca*), as well as a minke whale (*Balaenoptera acutorostrata*) porpoising from the area as the ship approached. Researchers operating hydrophones from vessels in the Strait and from shore on San Juan Island reported receiving acoustic signals that they identified as sonar sounds. The National Marine Fisheries Service (NOAA Fisheries) also received reports from witnesses that the sonar sound was audible in air.

The observations on 5 May were highly publicized and resulted in heightened public interest and concern that naval sonar activity may have contributed to the porpoise strandings in May. NOAA Fisheries met with representatives from the Navy to discuss the observations and hydrophone recordings and the activities of the *USS SHOUP*. The Navy confirmed that the *USS SHOUP* was conducting a swept channel exercise on 5 May which included the use of an active mid-range tactical sonar system (AN/SQS-53C). NOAA Fisheries provided copies of recordings and video received from the community to the Navy and advised that the agency would conduct thorough post mortem examinations of the porpoise carcasses recovered during the May time period. The examinations were conducted to investigate the cause of death for each stranded animal and to determine whether physical findings from the bodies and specimens linked any strandings with naval sonar activities.

NOAA Fisheries assembled a multi-disciplinary team of scientists and experts to conduct forensic post mortem examinations and to analyze the data for evidence of acoustic

impacts (Appendix C). The team included marine biologists, veterinarians, veterinary pathologists, research scientists and anatomists specializing in neuroanatomy, life history and trauma assembled from federal and State agencies, universities and research institutions. NOAA Fisheries contracted a local medical imaging company to obtain high resolution CT scan images from the carcasses.

This report summarizes past porpoise stranding reports, available information on the discovery and collection of specimens from individual porpoise stranding events from 2 May – 2 June 2003, gross findings from the examinations by the multidisciplinary team, the analysis of the high resolution CT images and preliminary results and conclusions drawn from the stranding investigation.

BACKGROUND

The Stranding Network receives reports mostly from private citizens about stranded porpoises found on beaches or floating in the near-shore waters of Washington State in all months of the year. The number of reports received is subject to change according to beach attendance and public motivation/interest in responding to strandings. Stranding response in Washington State has increased in the past few years in part due to implementation of the Washington State University/ Island County Beachwatchers Program on Whidbey and Camano Islands in the late 1990s and through funding to support stranding network operations from the NOAA Fisheries John H. Prescott Marine Mammal Rescue Assistance Grant Program.

Harbor porpoises are found along outer coastal beaches and around the inland waters of the state (Calambokidis *et al.*, 1987; Calambokidis *et al.*, 1997). The number of porpoise stranding events fluctuates annually and seasonally and varies by area. Dead animals comprise the majority of reported porpoise stranding events and the number of animals reported varies seasonally and from year to year. From January 1992 through December 2002, 66 harbor porpoise stranding events (in two of the reports, two animals stranded for a total of 68 individuals) were confirmed and/or investigated by members of the Network (NOAA Fisheries, unpublished data – Appendix D). Annually, total number of harbor porpoise stranding reports range from a low of zero in 1996 to a high of 15 in 2001 (Appendix D). The average yearly stranding event rate for harbor porpoises 1992-2002 was 6.0 per year (SD = 6.1).

Historically, spatial distribution of reported harbor porpoise stranding events has been highest in three main areas of the state where response effort and/or harbor porpoise density is greatest: (1) the San Juan Archipelago where there is both a high response effort and high density of porpoises; (2) Long Beach Peninsula where there is high population of private citizens during the summer months; and (3) the northwest corner of the state where there is high response effort. Between 1992 and 2002, there were 53 reports (80%) from the inland waters, compared to 13 reports from the outer coastal beaches (Table 2).

Figure 1 shows the spatial distribution of the strandings of the animals included in this report. A majority (86%; n = 12) of harbor porpoise strandings took place in inland

waters compared to the outer coast. More specifically, the inland water strandings were reported in 3 counties: (1) San Juan County (n = 4); (2) eastern Clallam County (n = 5); and (3) Island County (n = 3). All the strandings took place in May except one which occurred during the first week of June.

Temporally, 27 (41%) of the total harbor porpoise strandings between 1992 and 2002 coincided with the late spring and early summer months (April - June) and ranged from a low of zero in 1996 to 8 during these months in 2001 (Table 3). Eight stranding events took place in April (30%), 16 in May (59%) and 3 in June (11%). The number of harbor porpoise strandings during April – June, 2003 was double the number reported in the previous highest year (2001). While this investigation focused on harbor porpoises that stranded in the time period surrounding the 5 May *USS SHOUP* activities, marine mammal strandings which occurred from 1 April – 30 June (Appendix E) were also reviewed to look for any unusual stranding patterns.

MATERIALS AND METHODS

Network participants investigated 14 reports of individual harbor porpoise strandings and collected whole carcasses or heads from 11 porpoises that could be located based on information from initial sighting reports. Responders noted body conditions ranging from fresh dead to advanced decomposition when the specimens were collected in the field and obtained photographs of some carcasses. The elapsed time from earliest known report date to examination/collection by a network participant ranged from hours to several days. Therefore, carcass condition codes on the date of initial observation did not always agree with the condition code at time of necropsy. Level A data were collected, but additional detailed information (e.g., time of day and position of animal) at initial observation was not documented in a standardized fashion due to varied individuals responding to the strandings.

Upon collection, specimens (carcasses/heads) were assigned a field identification number (Field ID) by the stranding network responder, tagged and transported either directly to Seattle or to local freezers where they were held frozen (-20 F degree) pending later processing and necropsy (see Table 4 for listing of freezer types and specifications). Frozen specimens were transported from field locations and to/from the scanning facility in a truck mounted chest freezer to avoid thawing. Ultimately all specimens were transferred to and held at the NOAA Fisheries/National Marine Mammal Laboratory (NMML – Building 32) for examination. As each stranding report was received by NOAA Fisheries, it was assigned a unique NOAA Fisheries Registration Number. Registration Numbers do not always correspond to the chronological order in which animals have stranded, as these numbers are assigned when the Level A Stranding Reports reach the Fisheries office. A new tag with a NOAA Fisheries Registration Number was added to each carcass, and this number became the sole ID number used to identify specimens throughout the imaging and necropsy procedures (Table 1). Once the carcasses were frozen, NOAA Fisheries staff avoided thawing and/or re-freezing during subsequent handling until the specimens were prepared for post mortem examination.

The multidisciplinary team identified appropriate equipment and determined the protocols for conducting high resolution computerized tomography (CT scanning) and necropsies of the carcasses. In addition, a number of scientists involved in ongoing porpoise studies were contacted regarding protocols for collecting samples for their studies. A blind study approach was implemented during scanning, necropsy examination and data collection. The original Field ID tag remained with the carcass, but was covered by a taped bag so that the investigative team had no access to date and locality information. This helped prevent bias by team members during their investigation regarding locality and timing of strandings in relation to the *USS Shoup* activities.

Six whole carcasses and two heads were selected by NMFS for scanning based on the following criteria: (1) date of stranding; (2) locality of stranding; and (3) carcass condition. The specimens with the best carcass condition were selected for scanning and represented a range of dates before, during and after May 5. The selected specimens were transported in a truck mounted chest freezer to a local medical imaging facility, scanned on 20 July 2003 and returned to NMML. Scans were obtained at the scanning facility and formatted as a series as transaxial head and body images in both soft and bone windows using a spiral scan protocol. All scans were conducted with the body in a prone position, rostrum first. Images provided had variable slice thicknesses of 1-8 mm in bone and soft tissue protocols. The majority of scans were performed at 120 kV/250 MA. At the time of analyses, reformatted images were also produced, comprising soft tissue and bony windows of the head and body with expanded views of the brain and ear in transaxial, sagittal and coronal planes to optimize ear and brain detail from the available images. Three-dimensional reconstructions of some head structures were also produced (see Figures 21 and 32).

Following the scanning, carcasses were sorted and selected for thawing prior to necropsy based upon carcass condition. The “freshest” appearing carcasses were thawed for examination first.

Gross examination

A total of 10 porpoises were examined during the necropsy session. Two to four carcasses at a time were thawed overnight in an aluminum casket filled with cold tap water. Data were collected and recorded on the Specimen Record, Evaluation of Human Interaction, Phocoena Mass Dissection, Cetacean Body Surface Area, and Blubber Thickness/Mass data sheets for general body examination and the Marine Mammal Sensory Group Cetacean Necropsy Report for examination of heads and auditory structures. Collection of samples was tracked on a separate data sheet.

Comprehensive classical forensic and necropsy examinations were performed on each animal, including screening for pathogens, disease states and traumatic injury. On 22 July, the first two carcasses were removed from the thawing water and post mortem examinations were conducted according to prearranged protocols. On 23 July, necropsies were performed on four carcasses and one head. On 24 July, the remaining four carcasses were necropsied. Descriptions of body condition (nutritional status of the

animal) and carcass condition (freshness of the carcass) are described for each animal examined (Table 5). Post mortem scavenging, freeze artifact and autolysis hindered gross and microscopic tissue analysis of most specimens. Some protocols for data collection and sampling were conducted only on specimens of sufficiently high quality carcass condition. One head sample that had been scanned was determined to be too decomposed to provide useful information or samples during necropsy.

Histopathology

During the necropsy examination, entire organs or parts were removed from the carcass to a clean area for examination. Tissues and samples for diagnostics and histology were collected according to standard necropsy protocols, fixed/preserved for analysis and distributed to labs under MMPA Permit Number 932-1489 and CITES Permit 3US020950/9. Brains were extracted and examined. Only those of sufficient quality were sampled for histopathology.

Age determination

Teeth were extracted from each specimen for age determination by sectioning and counting of growth layer groups (to be performed at NMML).

Blubber Analysis

Full-thickness blubber samples were taken for chemical contaminant and lipid analyses using gas chromatography/mass spectrometry (GC/MS) for a wide suite of persistent organic pollutants (POP), including PCB congeners, DDTs, hexachlorobenzene and chlordane. POPs were extracted from blubber samples using an accelerated solvent extractor (ASE) (Sloan *et al.*, in prep). Lipid concentrations of the blubber samples were determined gravimetrically by measuring total non-volatile extractable material (reported as percent total lipids) (Sloan *et al.*, in prep).

Other analyses

Other analyses included polymerase chain reaction (PCR) for Morbillivirus, *Brucella* and *Mycoplasma*, fecal floatation and sedimentation examination for parasitology, domoic acid analysis of intestinal contents, stomach prey species analysis, aerobic bacterial cultures (Table 6), analyses of vitreous for blood urea nitrogen (BUN), calcium, phosphorous and magnesium (Table 7) and trace mineral analyses and vitamin A of liver and kidney (Table 7). As with samples for bacteriology, the suitability of samples for virus isolation was directly related to their quality and the freshness of the carcass. Viral culture was attempted in all specimens examined.

RESULTS

All animals had some degree of congestion, or red discoloration of the meninges, calvarium or cerebral surface, and in some cases of all abdominal tissues. This staining was attributed to postmortem autolysis and repeated freeze-thaw effects. This artifact hampered all gross and histological evaluation. Based on standardized carcass decomposition categories for the U.S. National Stranding Network (Geraci and Lounsbury, 1993), three porpoises were code 2 (fresh dead), six were code 3 (moderate decomposition) and the rest in code 4 (advanced decomposition). Individual cases are

presented here in chronological order of stranding and not by sequential NOAA Fisheries Registration Number. For each animal, comprehensive body composition data are listed in Table 5.

03NWR05001

History

This harbor porpoise was discovered dead floating off of Neck Point on Shaw Island (Figure 1) on 2 May 2003, collected and transferred to the University of Washington/Friday Harbor Lab (UWFHL) freezer on San Juan Island. The carcass was subsequently transferred to the NOAA/National Marine Mammal (NMML-32) freezer on 2 July 2003. No photograph of this animal at stranding was available.



Figure 2 – Right lateral photograph of the head of porpoise 03NWR05001 at time of necropsy (24 July 2003) (Photo: B. Hanson).

Gross Findings

An immature 136 cm total length, 39 kg female harbor porpoise (*Phocoena phocoena*) was presented dead, 24 July 2003, in good body and fair post mortem condition. Throughout the flanks, there was extensive scavenger damage with no evidence of human interaction. Within the blubber and hypodermis of the mid-dorsal region of the melon, rostradorsal quadrant of the left eye and right mandibular fat pads, there were multiple variably sized dark red foci. Multiple superficial contact abrasions and lacerations were noted in the skin above the left eye and lower lip. The ventral fascial musculature and blubber were degraded. The oral cavity and nares contained a moderate amount of dark red, serous fluid and the larynx appeared normal.

Nervous system: In the central nervous system, a small amount of clotted blood surrounded the basioccipital region, left inferior temporal area and cervical spinal cord. The cerebral meninges were diffusely dark red and there was a moderate amount of dark

red fluid beneath the pia and dura mater. Within the peribullar space of the right ear, there was an extensive accumulation of dark red gelatinous material (clotted blood).

Respiratory System: Diffusely, the lungs were dark red, moist and glistening (congestion), with a small amount of stable red foam within the trachea and bronchi. Widely dispersed throughout the pulmonary parenchyma, there were a few 1mm white calcified parasitic nodules.

Digestive system: The pancreas was dull brown to red with mild periductular fibrosis.

There were no overt lesions within the cardiovascular, endocrine, hemolymphatic, urogenital or musculoskeletal systems.

CT Findings

Cranial, thoracic and abdominal images were analyzed.

Cranial soft tissues: All soft tissues of the head were in relatively poor condition with some separation of tissue layers and multiple air pockets. The fatty layers on the right side of the head were noticeably degenerated. The soft walled nasal passages were poorly defined and collapsed, but the sinuses were normal with good pneumatization.

Intracranial/brain: All skull features were normal and the brain was intact. There were extensive regions of extravasated fluid with an HU rating of 27-40 compatible with blood in the skull base and basioccipital regions with minor accumulations in the temporal areas. Cranial scans suggested broad post mortem degenerative changes with poor preservation of most structures. The intracranial spaces had moderate to extensive areas of fluid accumulation, consistent with post mortem seepage and dependent pooling of blood. There were no well-defined areas of hemorrhage, but due to poor tissue quality, it was not possible to differentiate pre vs post mortem blood deposits. A small area in the mid-melon region appeared to be contused. The mandibular structures and head musculature were largely autolyzed and poorly preserved. There was no evidence of well-demarcated hemorrhage or contusion within the brain.

Eyes: Both eyes were present; however, the left globe was collapsed and the lenses were displaced ventrally in both eyes.

Peribullar region: There was an extensive soft tissue mass in the left medial peribullar space that had irregular, but well-defined margins and attenuation values consistent with peribullar parasites. The sinuses were well pneumatized. There was also minor clotting in the retrobullar spaces bilaterally.

Internal auditory canal (IAC)/Acousto-Vestibular/Facial Nerve: The internal auditory canals were well-defined with no evidence of blood or other abnormal material.

Middle ear: The middle ear cavities were normal with intact and normally configured

ossicles and round windows. A small moderate density mass at the right window was consistent with a minor blood clot.

Inner ear: The canals were symmetrical and normal in appearance. There was no evidence in the available scans of abnormal intracochlear blood or other cochlear compromise.

Post-cranial features: Fatty tissues throughout the body were poorly preserved. Thoracic scans showed partial congestion and atelectasis of the right and to a much lesser extent, left lungs. There were few small, discrete, high density inclusions in both lungs consistent with calcified parasitic granulomas.

Gross Findings and Final Diagnoses

- 1). Cerebrum, meninges: Congestion, multifocal, moderate.
- 2). Liver: Hepatitis, portal, mild, multifocal with biliary ductular hyperplasia and periductular fibrosis
- 3). Ear, peribullar (Gross diagnosis): Hemorrhage, moderate, focally extensive with intralesional nematode parasites
- 4). Lung: Bronchopneumonia, granulomatous and eosinophilic, multifocal, mild, with few adult and larval nematodes.
- 5). Skin, right mandible, dorsal to left eye, and labia (Gross diagnosis): Abrasions, moderate, multifocal
- 6). Hypodermis, midmandible and melon: Contusions, multifocal, moderate (Gross diagnosis)

Comments and Conclusions

Postmortem scavenging, autolysis and freeze artifact hampered histological evaluation of examined tissues. Overt pathologies consistent with acoustic trauma were not apparent. The cause of death of this animal could not be determined. The body condition was good and based on the axial muscle mass, was considered within normal range (Table 5). The most significant necropsy findings included an organized clot around the spinal cord and basioccipital region, midmandibular and midmelon contusions, and dark red fluid beneath the cerebral meninges. Although extravasated fluid compatible with blood was noted grossly and in CT scans, there were no well-defined areas of hemorrhage in the intracranial spaces. Poor tissue quality precluded making any conclusions about pre- or post mortem hemorrhage or extravasation. These changes are likely due to perimortem agonal thrashing; however, antemortem physical trauma cannot be ruled out.

Multisystemic parasitism is a common finding in wild porpoises and when mild, as in this case, it is not usually clinically significant. The pulmonary nematodes were most likely *Halocercus* spp. and the hepatobiliary change was likely due to *Campula* spp.

Microbiology isolated light mixed growth of *Pseudomonas* spp, alpha *Streptococcus* spp, nonhemolytic *Escherichia coli* and heavy growth of *Clostridium perfringens* from the intestine, and either light mixed or solitary growth of *Pseudomonas* spp, nonhemolytic *E. coli* or *Acinetobacter johnsonii* from multiple internal viscera (Table 6). No *Salmonella* spp were isolated from the small intestine. Based on the lack of significant attendant inflammatory infiltrate and with the extent of autolytic change in examined tissues, these

bacteria were considered post mortem invaders. Fecal floatation and sedimentation were negative for parasites. There was no detectable domoic acid within ingesta as determined by solid phase extraction (SPE) and analysis by high pressure liquid chromatography (HPLC). PCR of pooled lung, lymph node, spleen and brain was negative for Morbillivirus and consensus *Brucella* spp and follow up viral culture on Mabin Darby and Vero cell lines was negative. Trace mineral and vitamin A analysis of the liver and kidney were within normal reference limits (Table 7).

03NWR05003

History

This porpoise was reported stranded at County Park on Dungeness Spit (Figure 1) on 4 May 2003. A non-veterinary primary responder performed a cursory gross examination of the carcass and determined that this animal was pregnant with a fetus presumed to be in the third trimester. Only the head and fetus were collected and frozen. A CT scan was performed on the head, but it was not examined further during the necropsy session due to advanced decomposition. No photograph of this animal at time of stranding was available.

CT Findings

Only cranial images were produced for this animal. The head was decapitated at the occiput and was heavily flensed.

Cranial soft tissues: The majority of soft tissues were removed on the right and dorsal surfaces of the head, including all dermis, fats, and musculature. The remaining tissues were in poor post mortem condition. The left mandibular fats, like the brain, had extensive areas of fissures and granular, crystalline regions that were indicative of freeze-thaw artifact that compromised the tissues. The narial passages were filled with high contrast material and could not be assessed. The sinuses were partially occluded with poor pneumatization.

Intracranial/brain: The skull was intact except for the right parietal region which was disrupted. A bone fragment penetrated deep into the right parietal and temporal lobes of the brain and lodged adjacent to the right lateral ventricle. The lack of brain density changes in this area suggested post mortem trauma. The brain was intact and had a uniform granular appearance, consistent with extensive freezer artifact and the effects of freeze-thaw cycles. The brain was severely autolyzed.

Eyes: The right eye was missing and the left globe was collapsed.

Peribullar region: The spaces were essentially normal bilaterally for an animal in this severe state of decomposition.

Internal auditory canal/Acousto-vestibular/Facial nerve: The internal auditory canals were normal with partial degeneration of cranial nerves VIII and VII.

Middle ear: The ossicles were intact and normally configured bilaterally, and the round and oval windows were intact.

Inner ear: The canals were symmetric and normal.

The head was mostly denuded of soft tissues, and the remaining tissues exhibited signs of freeze-thaw artifact which compromised tissue quality. There were broad post mortem degenerative changes with poor preservation of most structures. Although there was no evidence in these scans of abnormal intracochlear blood or other cochlear compromise, the poor state of preservation made conclusions about the health of these ears impossible.

03NWR05005

History

This harbor porpoise was initially observed on 4 May 2003 wrapped in a fishing net (Figure 3) on Jackson Beach, San Juan Island (Figure 1). The carcass was collected on 5 May and stored in the UWFHL freezer, then transferred to the NMML- 32 freezer on 2 July 2003.



Figure 3 – Porpoise 03NWR05005 showing initial presentation of animal entangled in a fishing net (4 May 2003) (Photo: Whale Museum).

Gross Findings

An immature 126 cm total length, 33.5kg (does not represent true body mass due to extensive scavenger damage and poor post-mortem condition) female harbor porpoise was presented dead, 24 July 2003, in good body and fair post mortem condition (Figure

4). The right side of the carcass had extensive scavenger damage that extended deep to the blubber and on the left dorsolateral aspect of the mid caudal peduncle, there were small superficial scavenger bite marks. Tubercles were present along the leading edge of the dorsal fin. The right eye was absent and the right mandibular fat pad avulsed by scavenging. Throughout the head and fascial region, there were extensive cutaneous abrasions; the left mandibular fat and underlying mandibular and rostral periosteum and bone were dark red. The periosteum was widely separated from the body of the mandible.



Figure 4 – Right lateral photograph of porpoise 03NWR05005 at time of necropsy (24 July 2003). Due to lack of cutaneous net impressions, the entanglement was considered post mortem. The loss and fissuring of skin along the lateral aspect of the flank is attributed to post mortem decomposition and desiccation (Photo: B. Hanson).

Nervous system: The inner aspect of the calvarium and cerebral surface were diffusely dark red (Figure 5). At the level of the occipital condyles, the dorsolateral aspects of the spinal cord were invested with a moderate amount of dark red gelatinous material. A few nematodes were present in the left peribullar space with accompanying hemorrhage. No parasites were apparent in the contralateral peribullar space.

Digestive system: Within the porta hepatis, a sparse number of subcapsular bile ducts were variably dilated by trematodes interspersed within small to moderate amounts of black mucoïd deposits. Serial sections of the pancreas disclosed mild periductular fibrosis. A small number of nematodes were noted within the first compartment of the stomach. There was a moderate amount of chyme throughout the mesenteric lymphatics.

Respiratory system: The left lung was mottled dark red to pink and slightly depressed with few intervening light pink areas. Pink froth was present within the lumen of major bronchi.

There were no apparent lesions within the cardiovascular, urogenital, hemolymphatic, musculoskeletal or endocrine systems.

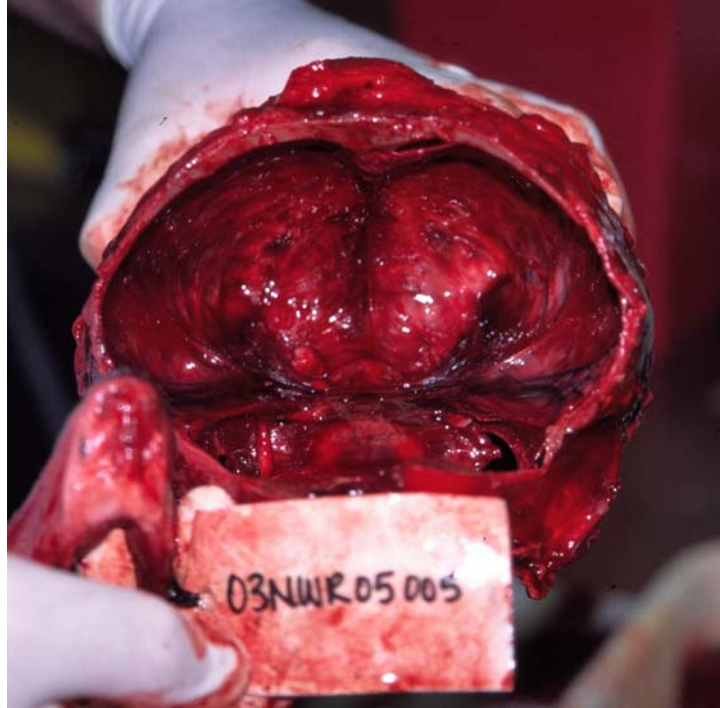


Figure 5 – Porpoise 03NWR05005 – The calverium has been removed and the superficial aspect of the brain exposed. Note the diffuse red black discoloration of the superficial aspect of the brain. This change is associated with freeze artifact and post mortem decomposition (Photo: B. Hanson).

CT Findings

This animal was not scanned.

Gross Findings and Final Diagnoses

- 1). Cerebrum, meninges; mandibular fat pad; peri-spinal fat; larynx, fibroadipose tissue and periosteum: Congestion, multifocal, moderate.
- 2). Cerebrum: Meningoencephalitis, lymphocytic, multifocal, mild.
- 3). Liver: Cholangiohepatitis, granulomatous and eosinophilic, multifocal, moderate, with biliary ectasia, periductular fibrosis and many trematode eggs and adults.
- 4). Lung: Bronchopneumonia, granulomatous and eosinophilic, multifocal, mild, with many nematodes.
- 5). Peribullar space, left (Gross diagnosis): Hemorrhage, mild, focally extensive, with intralesional nematodes

Comments and Conclusions

Autolysis, freeze artifact and post mortem scavenging impeded gross examination and microscopic assessment of multiple tissues. Although this animal was wrapped in a net on initial recovery, the lack of cutaneous (web) impressions suggests that this entanglement likely occurred post-, rather than antemortem. Cytology of the frozen lung airways failed to reveal any algae suggestive of agonal salt water aspiration. Based on a higher than normal blubber mass and despite slightly reduced axial muscle component this animal was graded in good body condition (Table 5). The extensive areas of

cutaneous abrasion along the left side of the head were consistent with contact, movement along rough substrates, and scavenger attacks. Subjacent to the abraded areas, there was multifocally extensive congestion of left lateral jaw fats, consistent with an agonal or terminal process. The nares were clear with no sign of contusion or hemorrhage. The grossly noted discoloration of the brain and calvarium is due to post mortem autolysis and freeze-thaw artifact within the superficial neuropil (Figure 5). There was no microscopic indication of acute hemorrhage in the examined brain sections. The mild meningoencephalitis was nonspecific and would not likely have been clinically significant. The multisystemic parasitism (retrobulbar, hepatic, pulmonary and enteric) in this animal is commonly observed in wild harbor porpoises. The biliary parasites were most likely *Campula oblongata* and would not have contributed significantly to impaired liver function. The lungworm infection was low grade and likely due to *Halocercus* spp and the unilateral, peribullar nematodes were morphologically consistent with *Stenurus* spp. The gastric nematodes were most likely *Anisakis* spp. In published case reports of harbor porpoise parasitism, infection is commonly recognized (Raga *et al.*, 2002). Aerobic culture yielded light variable mixed growth of *Aeromonas hydrophila*, *Enterobacter* spp, *Pseudomonas* spp from multiple internal viscera and heavy growth of *Clostridium perfringens* from the intestine (Table 6). No bacteria were isolated from the urine or kidney and fungal culture of the lung and lymph nodes was negative. Based on the extent of decomposition and lack of attendant inflammatory infiltrate in select tissues, these bacterial isolates were most likely post mortem invaders. With the exception of calcium values, trace mineral analysis of the liver and kidney proved within normal reference limits (Table 7). The increased liver calcium levels were likely due to dystrophic mineral deposition associated with the chronic cholangiohepatitis and the markedly reduced vitamin A values were presumably related to the extent of autolysis. Interpretation of the eye fluid analysis results was hindered due to the lack of available normal data in this species; based on extrapolation from terrestrial mammals, the calcium, magnesium, phosphorus and BUN appeared elevated and these increased values most likely represented post mortem change (bacterial overgrowth, putrefaction), blood contamination, or less likely, systemic homeostatic derangements associated with impaired renal function. The cause of death of this animal was not evident.

03NWR05006

History

This porpoise was found and collected at South Beach on San Juan Island (Figure 1) on 5 May 2003 and stored in the UWFHL freezer with subsequent transfer to the NMML-32 freezer on 2 July. No photograph of this animal at time of stranding was available.

Gross Findings

An adult 152 cm total length, 48.5 kg female harbor porpoise with moderate reproductive activity (corpora lutea in ovaries) was presented dead, 23 July 23, 2003, in moderate body (Table 5) and in very poor post mortem condition (Figure 6). The epidermis was missing throughout the ventrum and along the left flank. Extensive abrasions were present throughout the external surface of the head with gravel and debris filling the

laryngeal cavity, esophagus and nares. The ventral fats and musculature of the head were degraded.

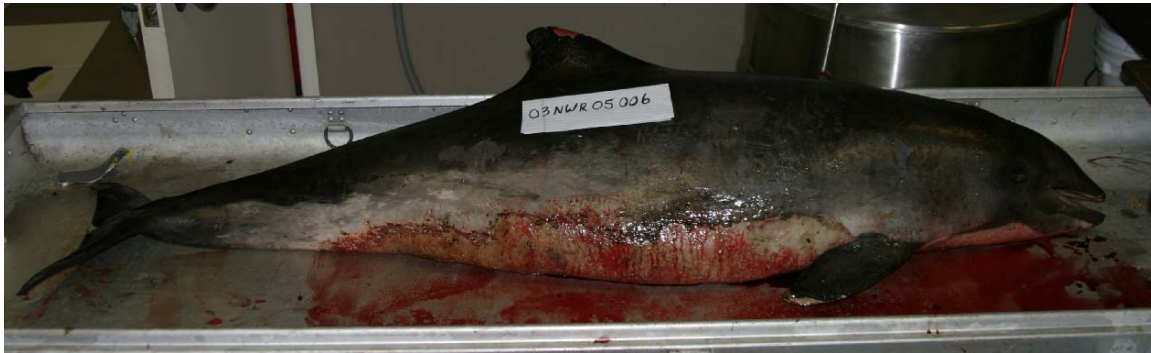

Figure 6 – Right lateral photograph of porpoise 03NWR05006 at time of necropsy (23 July 2003) (Photo: B. Hanson).

Nervous system: There was dark red fluid within the subdural space, and the basioccipital bone was dark red. Within the right retrobullar and peribullar spaces, there was a moderate amount of dark red fluid. There was a moderate amount of congestion of the cerebrum with red discoloration of the surface and subdural pooling of dark red fluid.

Respiratory System: The lungs were homogeneously dark red (congestion), with a few scattered 1mm hard white foci throughout the parenchyma. There was a small amount of red foam within the airways.

Cardiovascular System: There was a moderate amount of fat surrounding the coronary arteries.

Digestive System: There was a moderate amount of sand throughout the oral cavity. The pancreas and intestines are autolyzed. The liver had two firm, 2-3cm, well delineated black to red areas on the capsule. Bile ducts in the underlying parenchyma were ectatic with thick walls. There were a few trematodes within the lumen. Within the nonglandular compartment of the stomach there was a 3 x 2 x 1 cm raised area with a few crateriform ulcers containing 30-40 attached nematode parasites (*Anisakis* spp.) while the forestomach contained 2,000-3,000 free-floating nematodes.

Significant lesions were not apparent in the urogenital, endocrine, musculoskeletal and hemolymphatic systems.

CT Findings

Cranial, thoracic and abdominal images were analyzed.

Cranial soft tissues: A majority of tissue suites were intact, but in relatively poor condition. The right mandibular fats were well-defined, and the left lateral fats subjacent to the abraded skin had mid-low density regions suggestive of either congestion or extravasated blood.

Intracranial/brain: The skull appeared normal. The brain was intact, but subregions were poorly defined, suggesting moderate to severe autolysis. There were extensive areas of extravasated fluid with a HU density compatible with blood in the subarachnoid and subdural regions. As the meningeal divisions were poorly defined, determination of the precise fluid distribution was not possible.

Eyes: Both eyes were present; however, the left globe was collapsed and the lens was absent. In the right eye, the lens was displaced ventrally.

Right ear: There was an extensive soft tissue mass in the right dorsal peribullar space that was consistent with an organized clot. The internal auditory canal was well-defined with no evidence of blood or other abnormal material. Cranial nerves VIII and VII were normal. The middle ear cavity, ossicles and round window were normal (Figure 7). There was a minor blood deposit at the right round window.

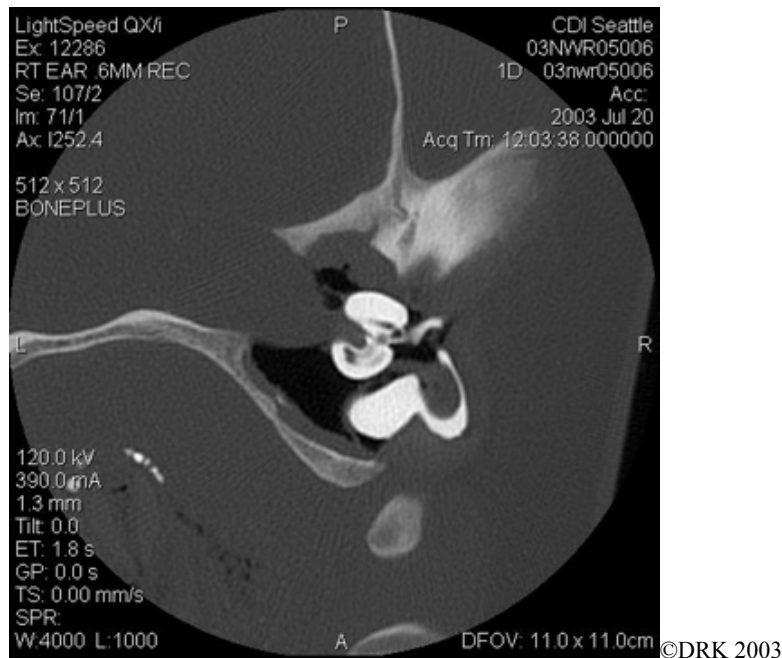


Figure 7 – CT scan image at level of ossicles of right rear (03NWR05006) (Image: D.R. Ketten).

Left ear: The peri and retrobullar spaces were normal. The left tympanic bone was possibly partially demineralized. The internal auditory canal was normal as were cranial nerves VIII and VII. The middle ear cavity, ossicles, and round and oval windows were normal.

Post-cranial features: There were extensive abrasions across most of the body. Thoracic scans showed both lungs were collapsed and congested, with the right lateral lung more compromised than the left. There were substantial numbers (50-100) of small, high density parasitic nodules which were most evident in the anterior lobes of both lungs.

Gross Findings and Final Diagnoses

- 1). Colon: Colitis, subacute, multifocal, transmural, moderate, with peritonitis.
- 2). Lymph node: Lymphadenitis, subacute, multifocal, moderate, with lymphoid hyperplasia.
- 3). Lung: Bronchopneumonia, granulomatous and eosinophilic, multifocal, moderate, with many adult nematodes and larvae.
- 4). Forestomach: Gastritis, proliferative and ulcerative, lymphocytic and eosinophilic, focally extensive, moderate, with few adult nematodes.
- 5). Liver: Cholangiohepatitis, granulomatous and eosinophilic, multifocal, mild, with biliary ectasia, periductular fibrosis and many trematodes.
- 6). Ear, peribullar (Gross diagnosis): Hemorrhage, moderate, focally extensive with intralesional nematode parasites.

Comments and Conclusions

Although post mortem change hindered microscopic assessment of multiple tissues and precluded evaluation of select segments of bowel, death was likely attributed to salmonella septicemia. *Salmonella Newport* Group C2 was cultured from the lung, hilar lymph node, kidney, spleen, liver, thymus, mesenteric lymph node and small intestine (Table 6). The pulmonary alterations observed in the right lung on thoracic CT scans were compatible with the gross and histological findings of bronchopneumonia. A review of the literature disclosed a small number of previous case reports of *Salmonella enterica* (antigenic formula 4,12:a:-) in harbor porpoises (*Phocoena phocoena*) in Scotland (Foster *et al*, 1999); however, salmonellosis is more commonly identified in sea otters, harbor seals and captive walruses (Calle *et al*, 1995; Thornton *et al*, 1998). In an overview of marine mammal disease surveillance findings in Los Angeles (Schroeder *et al*, 1973), there was a single case report of *Salmonella Newport* in a California sea lion and in a subsequent publication, this serotype was identified in one of four and two of 18 (the latter consisting of both *Newport* and *Montevideo*) California sea lions at a rehabilitation facility in 2002 (Smith *et al*, 2002). These bacteria are highly adapted to a number of human and animal hosts that may present with a wide variety of lesions, such as a gastroenteritis or generalized septicemia. The precise source of the bacteria in this case is unknown. Some serotypes of *Salmonella* are capable of survival and propagation in salinity as high as 3.5%. Based on the transmural inflammatory infiltrate within segments of intestine, infection was most likely *per os* with subsequent intestinal colonization, proliferation and invasion. PCR of pooled lung, lymph node, spleen and brain was negative for Morbillivirus and consensus *Brucella* spp and follow up viral culture on Mabin Darby and Vero cell lines was negative. Chemical analysis of the intestinal contents was negative for domoic acid. Histopathology confirmed the grossly noted pulmonary, hepatic and gastrointestinal parasitism and revealed an intermediate grade enteritis, lymphadenitis and peritonitis. Fecal floatation and sedimentation disclosed a moderate number of gastrointestinal nematodes and sedimentation was unremarkable for trematode parasites. This intensity of parasitism is commonly identified in porpoises. Due to the extent of post mortem decomposition and scavenging, an accurate assessment of the body condition could not be made (Table 5). Trace mineral and vitamin A analysis of the liver and kidney were within normal in house reference limits (Table 7). No overt lesions consistent with acoustic trauma were noted on the CT

scans. Although there were no well-defined regions of hemorrhage in the intracranial spaces, the poor tissue quality precluded precise determination of deposition. The ears were poorly preserved, but essentially normal bilaterally.

03NWR05007

History

This porpoise was initially observed and collected at Dungeness Spit (Figure 1) on 6 May 2003, stored in the USFWS/Dungeness National Wildlife Refuge freezer and then transported to the NMML-32 freezer on 2 July 2003. No photograph of this animal at time of stranding was available.



Figure 8 – Left lateral photograph of porpoise 03NWR05007 at time of necropsy (22 July 2003) (Photo: J. Gaydos).

Gross Findings

A 145.5 cm total length, 38.5 kg, immature female harbor porpoise was presented 22 July 2003 in good physical and moderate post mortem condition (Figure 8). There were ample subcutaneous and abdominal adipose stores and the animal was well muscled (Table 5). Extending from the mid thoracic region to insertion of the peduncle, along the left ventrolateral aspect of the torso there was multifocally extensive post mortem scavenging. Along the left lateral aspect of the mid thoracic region, there were three small, well circumscribed circular scars. Throughout the right flank, there was variably extensive subcutaneous congestion and dependant stasis. Along the dorsolateral aspects of the peduncle, there were multiple 0.6-0.8 cm diameter superficial aggregates of diatoms. On incision of the subcutaneous tissue adjacent to both mammary glands, approximately 2 ml of tan orange, glistening viscous material exuded and within the lumen of the main mammary ducts, there was a solitary 3-4 cm long nematode parasite. Within the perineum, a small number of nematodes were widely dispersed throughout the subcutis.

Respiratory system: The right and to a much lesser extent left lung lobes were mottled light pink with variably sized intervening, mildly depressed dark red areas. There was moderate visceral pleural fat accumulation. A small amount of stable pink froth was present within the bronchi.

Digestive system: Within the hilar region of the liver, there were moderate accumulations of trematode parasites. The glandular compartment of the stomach was contracted and empty. Along varying levels of the pancreas, between 5-35% of the ductules were circumscribed by thin to moderately thick margins of fibrous connective tissue.

There were no apparent lesions within the cardiovascular, urogenital, nervous, musculoskeletal, or hemolymphatic systems.

CT Findings

Cranial, thoracic and abdominal images were analyzed.

Cranial soft tissues: All the tissues were in moderate to poor condition. The nares and oral cavity were filled with high density material attributed to sediment and sand. Both sinuses were partially opacified with the right more compromised than the left and containing some relatively high density material.

Intracranial/brain: The skull, cerebellum and midbrain were normal in appearance. In the subtemporal region of the brain, there were mid to low density accumulations that were consistent with pooled extravasated blood (Figure 9).

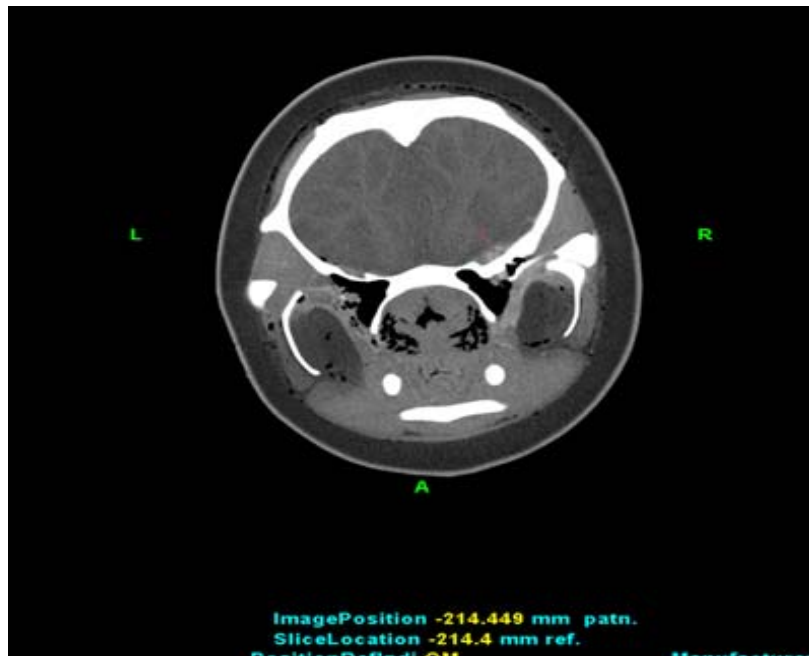


Figure 9 – CT scan image demonstrating mid to low density structures in the subtemporal region (03NWR05007) (Image: D.R. Ketten).

Eyes: The left globe was enucleated, but the right was present.

Peribullar region: The regions were clear and well aerated bilaterally with well-defined ligaments.

Internal auditory canal/Acoustic-vestibular/Facial Nerve: No indication of blood or other abnormal material was present. Cranial nerves VIII and VII nerves were intact but degenerated.

Middle ear: The cavities, ossicles and round windows were normal bilaterally.

Inner ear: The canal structures were symmetrical and normal in appearance. In both ears, there were minor mid attenuation deposits consistent with intracochlear blood.

Post-cranial features: Thoracic scans showed that the cranioventral lung lobes were congested and collapsed bilaterally, with the right more extensively affected than the left. Both lungs had multiple high density nodules or calcified cysts consistent with parasitic pneumonia.

Gross Findings and Final Diagnoses

- 1). Cerebrum, meninges and larynx: Congestion, diffuse, moderate.
- 2). Heart: Myocarditis, granulomatous and eosinophilic, multifocal, mild with a nematode adult.
- 3). Liver: Cholangiohepatitis, granulomatous and eosinophilic, multifocal, moderate, with biliary ectasia, periductular fibrosis and many trematode eggs.
- 4). Lung: Bronchopneumonia, granulomatous and eosinophilic, multifocal, mild, with nematode adults and larvae.
- 5). Mammary gland: Mastitis, lymphocytic and eosinophilic, chronic, multifocal, mild.
- 8). Pancreas: Fibrosis, periductular, mild, multifocal, chronic
- 9). Skin, right flank: Dermatitis, mild, multifocal, chronic (resolving scars) (Gross diagnosis) with hypodermal nematode parasites
- 10). Skin, left ventrolateral thorax: Laceration, mild, focal, subacute (Gross diagnosis)
- 11). Ear, intracochlear: Presumptive hemorrhage, mild, multifocal

Comments and Conclusions

There were no overt lesions within the examined tissues that would account for the death or stranding of this animal. Close evaluation of the oropharyngeal, peribullar and periorbital spaces failed to reveal any lesions consistent with an acoustic related trauma, and microscopic assessment of the larynx disclosed only low-grade mucosal erosion and congestion. Gross examination disclosed multifocal areas of pulmonary congestion which may have accounted for the CT findings. The ears were normal bilaterally by CT scan with some increased density in the cochlear canal consistent with intracochlear blood. Gross examination of the nares did not reveal any luminal deposits and the composition of the high density foreign material detected by CT scan is unknown. The scars noted along the right lateral aspect of the cranial thoracic cavity likely represented a long past traumatic or infectious process and appeared restricted to the superficial dermis. Cytology of the punctate, orange mucoid cutaneous deposits revealed numerous diatoms. Epidermal diatoms have previously been reported in Dall's porpoises (*Phocoenoides dalli*) in the Northern Pacific Ocean and are considered incidental findings (Holmes *et al.*, 1993). Trace mineral and vitamin A analysis of the liver and kidney proved largely within normal reference limits (Table 7); increased liver calcium is likely related to post

mortem mineral deposition or chronic inflammatory associated with the liver flukes. Examination of the aqueous humor disclosed significantly increased phosphorus and blood urea nitrogen relative to terrestrial animal values. Efforts are ongoing to determine normal reference values for small cetaceans and based on the lack of associated change within the examined tissue and degree of post mortem change, interpretation of these data is hindered; abnormalities with phosphorus levels may be associated with lactation or some other disease processes. Cytologic evaluation and bacterial culture of the grossly noted mammary gland discharge revealed abundant vacuolated and proteinaceous background with scattered exfoliated cuboidal and squamous epithelia, histiocytes, lymphocytes and fewer neutrophils with small numbers of extracellular cocci and bacilli. Histopathology disclosed a low grade, chronic inflammatory process presumably due to intra- and periductular nematode parasites. These parasites were morphologically consistent with *Crassicauda* spp; although the intensity of infection may have interfered with normal lactation, this burden is not considered pathologically significant. The bile duct parasites were most likely *Campulla* spp and the lungworms were presumably *Halocercus* spp. Multisystemic parasitism is commonly identified within wild stranded harbor porpoises and in this animal, cumulatively would not have contributed significantly to antemortem morbidity. Fecal floatation and sedimentation were negative for parasites. Aerobic culture of the milk isolated light growth of nonhemolytic *Streptococcus* spp and light mixed growth of *Pseudomonas fluorescens* and *Enterobacter* spp from the lung (Table 6). Based on the extent of post mortem change and lack of significant inflammatory infiltrate, these bacteria were likely post mortem contaminants. Aerobic culture of multiple internal viscera, including brain, mammary gland, spleen, spinal cord, rectal swab, thymus and thoracic fluid, yielded light growth of *Enterobacter* spp with no bacteria isolated from the kidney, urine, or liver (Table 6). Special culture for fungi and *Salmonella* spp were negative. In two of six sections of pancreas, the fibrotic scores were 5 and 35 percent. Analysis of intestinal contents for domoic acid was negative.

03NWR05008

History

This animal was first reported stranded on 6 May 2003 on Discovery Trail at Ennis Creek (Figure 1). The head was removed, collected for examination and delivered to the NMML-32 freezer on 9 May 2003 (Figures 10 and 11). The remainder of the carcass re-floated and was later retrieved on 16 May.

Gross Findings

The head of this adult male was presented on 22 July 2003 in poor post mortem condition (Figure 12). Throughout the head, there was extensive deterioration of blubber and fat pads. The melon was clear. Within the superficial mandibular fat pads, there was variable congestion and the deep pads were clear. Multifocal blubber degeneration and autolysis was noted subjacent to bird scavenging. A moderate number of (7-10) teeth were missing from the right mandible. The right eye was ruptured and collapsed (scavenged) and the left eye was autolytic. The remainder of the porpoise, 146 cm



Figure 10 – Left lateral photograph of head of porpoise 03NWR05008 three days (9 May 2003) after initially reported stranded (Photo: Olympic Coast National Marine Sanctuary).



Figure 11 – Head-on photograph of left lateral side of porpoise 03NWR05008 three days (9 May 2003) after stranding was initially reported, demonstrating the extent of scavenger damage (Photo: Olympic Coast National Marine Sanctuary).



Figure 12 – Left lateral photograph of head of porpoise 03NWR05008 at time of necropsy (22 July 2003) (Photo: D. Ketten).



Figure 13 – The remainder of porpoise 03NWR05008 at time of necropsy (24 July 2003) (Photo: B. Hanson).

truncated length, approximately 40 kg and with minimal reproductive activity, was presented 24 July 2003, in fair to moderate physical condition and poor post mortem state (Figure 13). The animal was fairly fleshed. Along the left lateral aspect of the mid thoracic and cranial abdominal region, there was focally extensive loss of the skin, blubber and scapula with maceration of the subjacent intercostal muscles. Within the inguinal region, there were a moderate number of subcutaneous and hypodermal calcified parasites.

Digestive system: Throughout the abdominal cavity, involving numerous loops of small intestine as well as the peritoneum and serosal surface of multiple viscera, there were multifocally extensive adhesions which were readily reduced by digital manipulation; on exposed surface, the serosa was finely granular. There was moderate enlargement of the

mesenteric lymph nodes. Multifocally within the liver, bile ducts were dilated with thickened walls and contained trematodes.

Urogenital system: The kidneys were detached from the peritoneal surface and free within the dorsal peritoneal cavity. Within the right epididymis, immediately dorsal to the testes, there was a 2 cm diameter, firm, nodule with multiple adhesions to the surface of the testes; on incision, there were abundant amounts of pale yellow white mucoid material bound by a moderately thick capsule.

Respiratory system: Bilaterally, the lungs were collapsed and the dorsal visceral pleura overlaid by abundant amounts of small pebbles and stones. On incision of the trachea and extending throughout the virtually the entire length of the caudal bronchi, the lumen contained a moderate amount of small stones. Within the lumen of the nasopharynx and nares, there were a moderate number of nematode parasites.

Nervous system: At the level of cervical vertebral 1 and 2 segmentally overlying the left ventral aspect of the spinal cord, there was a small amount of dark red gelatinous material. Interspersed within a small amount of blood, within the left peribullar region, there were moderate accumulations of nematodes. Smaller numbers of nematodes were noted in the right retrobullar area.

There were no apparent lesions within the musculoskeletal, hemolymphatic, cardiovascular, or endocrine systems.

CT Findings

Only cranial scans were conducted. The head was decapitated at the level of the occiput. Readings suggestive of degenerated tissues were observed as well as large deposits of high density material in the airways and esophagus, attributed to sand and sediment.

Cranial soft tissues: High density, mixed material occluded the lumen of the left and to a much lesser extent the right nares, particularly the left sac.

Intracranial/brain: The skull features were normal. The brain was relatively uniform in appearance, suggestive of poor preservation.

Eyes: The left eye was intact, and the right eye was present and the lens was displaced ventrally.

Peribullar region: The sinuses were generally clear bilaterally. A substantial, well-defined mass of tissue was present medial to the left tympano-periotic bone with a similar, but smaller mass, on the right which were consistent with bundled parasites (Figure 14).

Internal auditory canal/Acousto-vestibular/Facial nerve: The IAC, retrobullar areas, and cranial nerves VIII and VII were normal bilaterally.

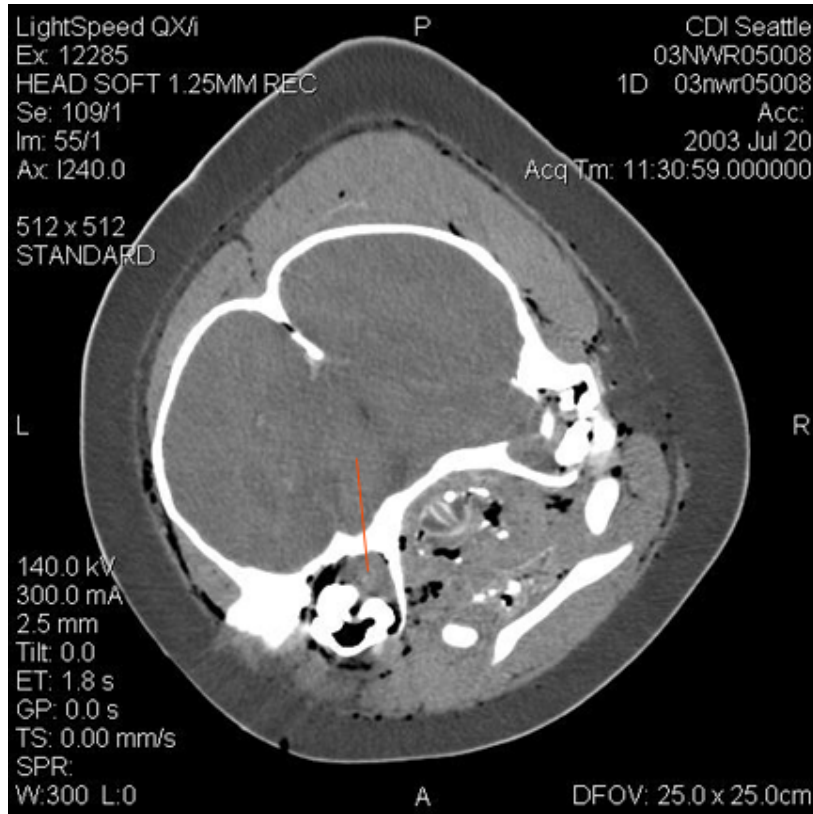


Figure 14 – CT scan image of 03NWR05008 at level of the tympano-periotic bone illustrating a tissue mass medial to the left tympano-periotic bone (orange arrow just below center of image) (Image: D.R. Ketten).

Middle ear: The cavities, ossicles, as well as round and oval windows were normal bilaterally.

Inner ear: The canals and intracochlear fluids were normal in both ears.

Gross Findings and Final Diagnoses

- 1). Intestine; liver and kidney: Serositis and capsulitis, fibrinous, multifocal, mild, with many bacilli and few cocci.
- 2). Epididymis: Abscess, focal, moderate, chronic, with nematode eggs.
- 3). Liver: Cholangiohepatitis, granulomatous and eosinophilic, multifocal, moderate, with biliary ectasia, periductular fibrosis and many trematodes.
- 4). Lung: Bronchopneumonia, eosinophilic and granulomatous, multifocal, moderate, with nematodes.
- 5). Blubber, inguinal region: Steatitis, moderate, multifocal, granulomatous, chronic with intralesional parasites (Gross diagnosis).
- 6). Peribullar space: Hemorrhage, mild, focally extensive, with abundant intralesional nematodes (Gross diagnosis).

Comments and Conclusions

Profound post mortem decomposition impeded microscopic assessment of multiple tissues and precluded gross and microscopic assessment of the larynx and adjoining oropharyngeal tissue. The widespread serositis and peritonitis likely contributed to death of this animal. Lesions indicative of acoustic-related injury were not evident. The CT analysis of this animal's brain, melon, skull, and ears was considered within normal limits for an animal of this code. Adequate nutritional assessment of this animal was hindered due to the extent of post mortem decomposition and scavenging (Table 5). Aerobic bacterial culture isolated light variable mixed growth of alpha *Streptococcus* spp, nonhemolytic *Escherichia coli*, *Enterobacter* spp and less frequently *Aeromonas hydrophila* from multiple internal viscera, including the epididymis (Table 6). Based on the extent of putrefactive change, it was difficult to resolve the precise contribution of any of these bacteria to the grossly noted peritonitis. The possibility of post mortem bacterial overgrowth and loss of a more fastidious pathogen could not be discounted. Histopathology of the epididymal abscess revealed numerous larvated nematode ova interspersed within abundant amounts of mineral deposition that was peripherally circumscribed by dense bands of fibrous connective tissue. The ova were suggestive of *Crassicauda* spp and were considered an incidental finding. No significant pathogens were isolated by routine culture of the epididymis and the abscess was negative for *Brucella* spp by polymerase chain reaction. The hepatobiliary (*Campula* spp), peribullar (*Stenurus* spp), pulmonary (*Halocercus* spp), gastric (*Anisakis* spp) and subcutaneous (*Crassicauda* spp) parasitism are commonly observed in wild porpoises; no parasites were identified by fecal floatation or sedimentation. No fungi were isolated from lung tissue. Trace mineral and vitamin A analysis of the liver and kidney proved within normal reference limits (Table 7). The small amount of clotted blood surrounding the cervical spinal cord was likely associated with agonal struggling. The avulsed left eye and cutaneous defects within the fascial region were attributed to post mortem scavenging.

03NWR05010

History

This porpoise was initially reported stranded on 13 May 2003 at Admiralty Head on Whidbey Island (Figure 1). At the time, the carcass was fresh with little superficial damage, but blood was found in both eyes, the nares and oral cavity (Figure 15). On the morning of 14 May, a portion of the head and right side of the body were scavenged (Figure 16). The carcass was wrapped in plastic and transferred to NMML-32 that evening.

Gross Findings

An adult, 154 cm total length, approximately 55 kg, harbor porpoise was presented dead, 24 July 2003 in fair body and very poor post mortem condition (Figure 17). Throughout the ventrum, there was widespread bird damage. From the ventral aspect of the left mandible to the mid thoracic region, there is focally extensive loss of skin and blubber with exposure of the ribs and intracostal musculature (post mortem predation). Along the leading edges of the fluke and flippers, there was extensive loss of epidermis. There was

a 10x12cm dark red, edematous area on the left abdominal wall that extended from the blubber moderately deep into the underlying muscle. Both mandibular fat pads were stained red, the left darker than the right. Both peribullar sinuses contained hundreds of nematodes.



Figure 15 – Right dorsolateral photograph of initial stranding of porpoise 03NWR05010 on 13 May 2003 (Photo: S. Dubpernell).



Figure 16 – Right lateral photograph of 03NWR05010 the morning of 14 May 2003, showing extensive scavenger damage to head and thorax (Photo: S. Dubpernell).



Figure 17 – Right lateral photograph of 03NWR05010 at time of necropsy (24 July 2003) (Photo: B. Hanson).

Nervous system: The left occipital crest was fractured. Along the fractured margins, the dura was dark red and separated from the underlying bone by dark red fluid. The internal surface of the calvarium and superficial aspect of the brain were diffusely dark red and the meninges were overlaid by a small amount of dark red fluid.

Respiratory system: The lungs were diffusely dark red and congested with rare 1 mm calcified white nodules. There was a small amount of dark red fluid in the airway.

Digestive system: Within the liver hilus, there were a few firm 1-2 cm diameter irregular subcapsular bile ducts that were moderately dilated by trematode parasites and black green tenacious material. Bile ducts within this area had thickened walls. The pancreas was autolyzed and there was no indication of periductular or interstitial fibrosis.

There were no apparent lesions within the urogenital, endocrine, hemolymphatic or cardiovascular systems.

CT Findings

This animal was not scanned.

Gross Findings and Final Diagnoses

- 1). Bone, left occipital crest: Fracture, focally extensive, with hemorrhage (Gross diagnosis).
- 2). Adipose tissue, left mandibular fat pad; panniculus and skeletal muscle, left abdomen: Congestion, multifocal, moderate.
- 3). Adipose tissue: Atrophy, diffuse, mild.
- 4). Liver: Cholangiohepatitis, granulomatous and eosinophilic, multifocal, moderate, with biliary ectasia, periductular fibrosis and trematodes.
- 5). Lung: Bronchopneumonia, granulomatous and eosinophilic, multifocal, mild, with nematodes.
- 6). Ears, peribullar: Hemorrhage, moderate, focally extensive, with nematode parasites.

Comments and Conclusions

The most significant gross observation was the fractured left occipital crest with hemorrhage in the underlying tissues and left mandibular fat pad. Due to the lack of microscopic hemorrhage or inflammatory infiltrate, it was difficult to resolve whether this fracture was a post mortem event or incurred shortly before death, as there was insufficient time for a histological reaction to develop. The immediate cause of death is not evident; however, if this was a perimortem event, the trauma resulting in this fracture would have been sufficiently severe to account for the death of this animal. No overt lesions consistent with acoustic trauma were noted. The left abdominal subcutaneous hematoma was likely associated with blunt trauma. An adequate assessment of the nutritional status of this animal was not possible due to extent of post mortem decomposition (Table 5). The microscopically detected fat atrophy was indicative of a negative energy balance. The peribullar parasites were morphologically consistent with *Stenurus* spp and the heavy burden would have presumably contributed to antemortem morbidity. In contrast, the parasitic pneumonia (most likely *Halocercus* spp) and cholangiohepatitis (presumably *Campula* spp) are considered low grade and incidental. The parasitic load from these latter two species is commonly observed in wild porpoises and presumably would not have contributed at least moderately to antemortem morbidity. Fecal floatation and sedimentation were negative for parasites. There was no detectable domoic acid within ingesta as determined by SPE and analysis by HPLC. PCR of pooled lung, lymph node, spleen and brain was negative for Morbillivirus and consensus *Brucella* spp. Viral culture on Mabin Darby and Vero cell lines were negative. The pancreas was too autolyzed to score the extent of fibrosis. Trace mineral and vitamin A analysis of the liver and kidney were within normal reference limits (Table 7). Aerobic bacterial culture of the kidney, liver, mesenteric lymph node yielded light, mixed growth of *Enterococcus* spp, nonhemolytic *Escherichia coli*, and *Aeromonas hydrophila* (Table 6). There was moderate mixed growth of these bacteria in the spleen, lung and brain and heavy growth of *Enterococcus* spp and *Clostridium perfringens* from the small intestine. Based on the extent of autolysis and lack of attendant inflammatory infiltrate, these isolates are most likely due to post mortem overgrowth. There were no fungal pathogens isolated from the lung and special culture for *Salmonella* spp in the intestine was negative. Trace mineral analysis of the eye fluid (vitreous humor) revealed calcium levels of 7.7 mg/dl, magnesium of 20.79 mg/dl, a phosphorus of 64 mg/dl and a blood urea nitrogen of 57 mg/dl (Table 7). Although the BUN may appear elevated, the lack of established normal levels for healthy animals confounds interpretation of this data.

03NWR05011

History

The porpoise was first reported stranded at the high tide line on 16 May 2003 at Ediz Hook in Port Angeles (Figure 1), with blood coming from the eyes, nares, and oral cavity (Figure 18).



Figure 18 – Left ventral view of porpoise 03NWR05011 at time of initial discovery (16 May 2003) (Photo: Olympic Coast National Marine Sanctuary).



Figure 19 – Ventral photograph of 03NWR05011 at time of necropsy (23 July 2003) (Photo: B. Hanson).

Gross Findings

An adult 136.5 cm total length, 37 kg female harbor porpoise was presented dead 23 July 2003, in good nutritional and fair post mortem condition with extensive scavenger damage (Figure 19). Throughout the left dorsolateral aspect of the head there was extensive subcutaneous hemorrhage. There were bilateral fractures and disarticulations of the zygomatic arches, parallel transverse and comminuted fractures of the left mandible, and multiple rostral skull base, including frontal bone and prefrontal fractures frequently admixed with substantial amounts of acute hemorrhage or overlaid by variably sized blood clots (Figure 20). Intercalated between the oral mucosa and palatine lobes and occluding the pterygoid sinus there was marked hemorrhage. Frank hemorrhage was within the lumen of the trachea, bronchi, deep within the nares, esophagus and oropharynx. The vasculature appeared prominent in the blubber and nuchal fat. There were focal abrasions on the rostral mandible and maxilla and small healed cutaneous

lacerations along the leading edge of the dorsal fin, left fluke lobe and mid dorsal region of the caudal peduncle.

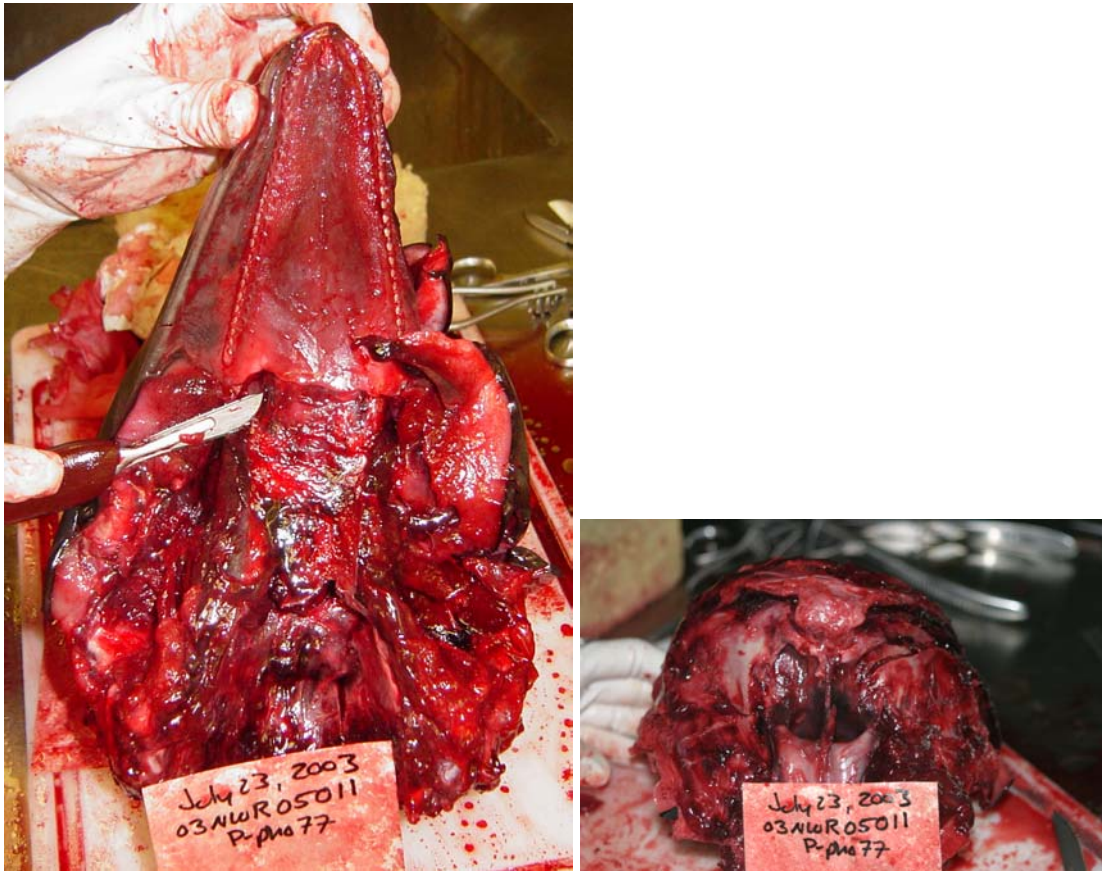


Figure 20 – Photographs of the ventral (left) and caudal (right) aspects of the skull of 03NWR05011 demonstrating multiple fractures (Photos: D. Ketten – left; B. Hanson – right).

Nervous system: Adjacent to the cranial fractures, there was extensive epi and subdural hemorrhage and the entire surface of the brain was dark red. In the left ear, there were numerous peribullar nematodes.

Cardiovascular and endocrine systems: Tissue surrounding the thyroid gland and thymus was dark red and moderately edematous. There was approximately 7 ml of dark red fluid within the pericardial sac.

Respiratory System: There was a moderate amount of dark red fluid within the trachea. The lungs were uniformly dark red, with rare 1mm white calcified parasitic nodules and there was approximately 75mL of dark red fluid within the thoracic cavity.

Digestive System: The pancreas was light red to pink and a minimal amount of fibrosis surrounded the pancreatic duct. Diffusely, there was a moderate amount of chyme within the mesenteric lymphatics. There was a small amount of dark green to brown ingesta throughout the intestines.

There were no apparent lesions within the urogenital or hemolymphatic systems.

CT Findings

Cranial, thoracic and abdominal images were analyzed. The animal was in generally poor condition, and had extensive trauma evident particularly on the surface and within the head.

Cranial soft tissues: There were multiple areas of abrasions with the most compromised areas rostral. Sand or similar material was present throughout the mucosal and cutaneous surfaces of the head, particularly in the left dorsal nasal sac. There were extensive areas of contusion consistent with cranial trauma.

Intracranial/brain: The entire skull was severely compromised by multiple fractures, including longitudinal and comminuted fractures of the skull base, right occipital, left temporal, left parietal, left squamosal, frontal and left mandibular bones, with multiple skull fragments displaced (Figures 21 and 22). The left mandible had two longitudinal fractures, three parallel fractures and one laterally displaced chip. The brain was homogenous, suggesting it was severely compromised as a result of the trauma inflicted on the skull.

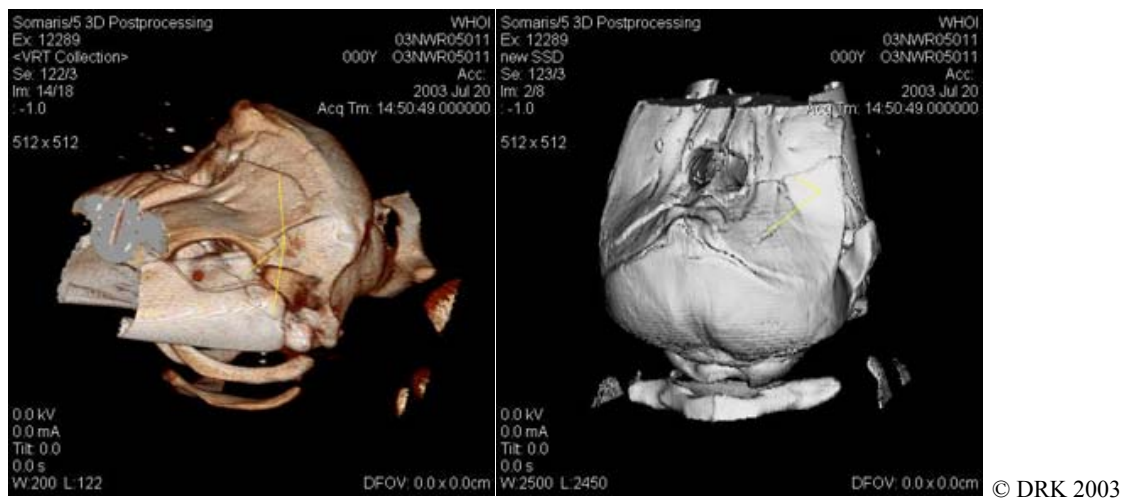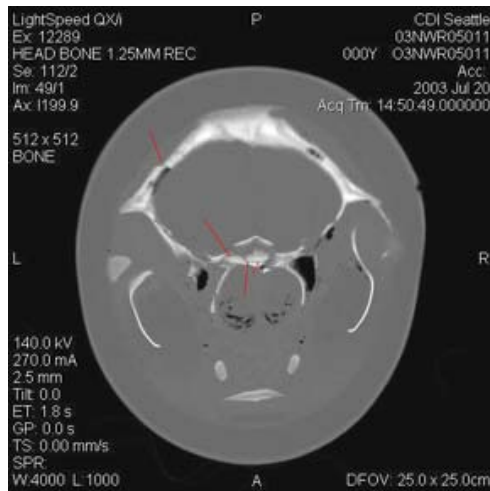


Figure 21 – A lateral 3D view (left) of 03NWR05011 showing the mandibular and frontal fractures (yellow arrows). The dorsal 3D view (right) shows a right frontal and maxillary fracture (yellow arrows) (Illustrations: D.R. Ketten).

Eyes: Both were present but collapsed.

Right ear: The peribullar areas and middle ears were appeared normal. Bilaterally, the inner ears contained blood in the apical and middle turns.

Left ear: Blood was found in the apical and middle turns of the inner ear. The peribullar space contained two tissue masses: one an organized clot and the other a mass medial to the left tympano-periotic bone, with a similar mass within the middle ear cavity.

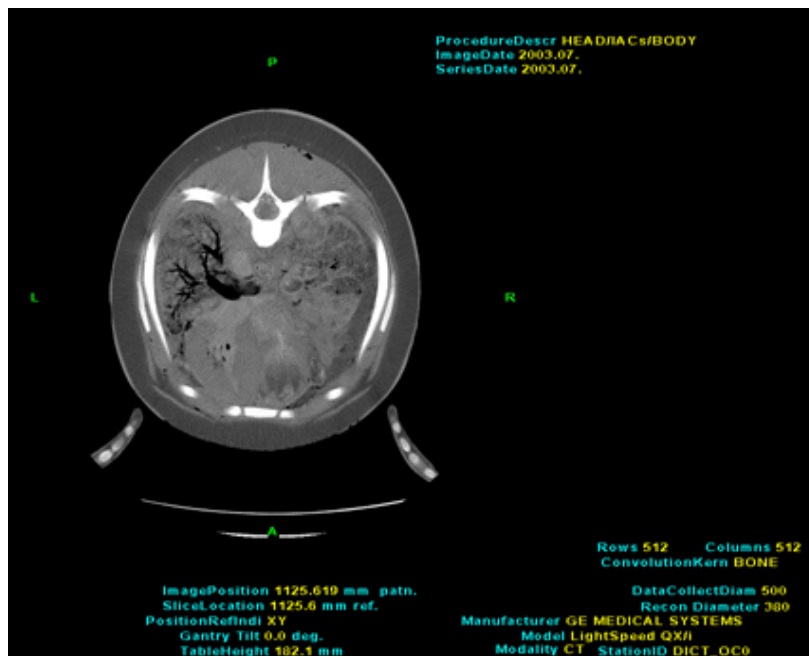


© DRK 2003

Figure 22 - A 2D cross section of 03NWR05011 demonstrating multiple fractures disrupting the brain case (orange arrows) (Image: D.R. Ketten).

Multiple, small, dense spheroids within these soft tissue masses were most likely calcified parasitic bodies. There was also a tympanic bone fracture in the left lateral wall.

Post-cranial features: The internal organs were partially autolyzed with some evidence of freeze-thaw artifacts within the liver. The lungs were congested and atelectatic with the right slightly more affected than the right. An ice block was evident in the right bronchus (Figure 23). Several dense foci within the trachea were attributed to sand or parasitic inclusions.



© DRK 2003

Figure 23 – A CT scan image of 03NWR05011 at the level of the right bronchus demonstrating an ice block (Image: D.R. Ketten).

Cause of death: Given that the evidence from the histology shows the fractures were pre or perimortem, the CT evidence shows extensive fractures to be consistent with a blunt or blast trauma that would likely have resulted in immediate or rapid death.

Gross Findings and Final Diagnoses

- 1). Cranium, rostral skull base, mandible, zygomatic arches, and frontal bones: Fractures, comminuted, severe, closed with variable displacement and hemorrhage (Gross diagnosis)
- 2). Adipose tissue, near mandibular fracture: Congestion, multifocal, mild.
- 3). Spinal cord and peripheral nerve: Hemorrhage, multifocal, mild.
- 4). Lung: Bronchopneumonia, granulomatous and eosinophilic, multifocal, mild, with few adult nematodes.
- 5). Liver: Cholangiohepatitis, granulomatous and eosinophilic, multifocal, moderate, with biliary ectasia, periductular fibrosis and trematodes.
- 6). Pancreas: Fibrosis, periductular, multifocal, moderate.
- 7). Thymus: Edema, interlobular, multifocal, mild.
- 8). Ear, peribullar (Gross diagnosis): Hemorrhage, moderate, focally extensive with intralesional nematode parasites.
- 9). Ear, intracochlear: Presumptive hemorrhage, mild, multifocal

Comments and Conclusions

Profound autolysis and freeze artifact hampered histopathology. The most significant findings were the skull and mandibular fractures, with grossly noted hemorrhage within the adjacent tissue. Post mortem changes hindered microscopic assessment of the adjoining fascia and periosteum and hampered precise determination of whether this trauma may have been incurred ante- or postmortem. If inflicted antemortem, the severity of the physical trauma would have been sufficiently severe to account for the loss of this animal. Detection of frank hemorrhage within the lumen of the nares and cochlea, as well as free blood within the trachea, bronchi, esophagus and calverium is suggestive of antemortem blunt trauma that presumably was inflicted by a predator, con-specific, or some other means. The tracheal and esophageal submucosal congestion was likely an agonal or terminal process possibly related to dependent hypostasis. Based on comparison within normal reference values, this animal was in good body condition (Table 5). Aerobic bacterial culture of the liver, thymus, spleen, mesenteric lymph node and urine isolated small numbers of *Enterococcus* spp. In the kidney and spinal cord, there was mixed light growth of *Enterococcus* spp and nonhemolytic *Escherichia coli* and heavy growth of *Clostridium perfringens* from the small intestine and colon (Table 6). No fungi were isolated by special culture of the lung or *Salmonella* spp from the intestine. Negative staining electron microscopy of the conjunctiva disclosed numerous mixed bacteria which are not considered pathologically significant and there were no discernible viral particles. There was insufficient cerebrospinal fluid to assay for canine distemper virus by serology. PCR of pooled lung, lymph node, spleen and brain was negative for Morbillivirus and consensus *Brucella* spp and follow up viral culture on Mabin Darby and Vero cell lines was negative. There is a possibility of reduced pathogen viability associated with post mortem decomposition and freezing. Urinalysis of post mortem urine disclosed dark yellow cloudy urine with a specific gravity of 1025

and protein of 300. No nitrates, ketones, bilirubin, casts, crystals, urobilinogen, mucus, bacteria, fat or white blood cells were detected. There were 1-2 white blood cells, 0-1 red blood cells per high powered field and large numbers of transitional epithelia. Trace mineral and vitamin A analysis of the liver and kidney proved within normal reference limits (Table 7). The hepatobiliary (*Campula* spp), pulmonary (*Halocercus* spp) and gastric (*Anisakis* spp) parasitism is commonly observed in wild porpoises; no parasites were identified by fecal floatation or sedimentation.

03NWR05019

History

This animal was reported stranded on 17 May 2003 at Lagoon Point on Whidbey Island (Figure 1). After examination of the animal at the site, it was wrapped in plastic to prevent further scavenging and moved above the high tide line (Figure 24). The carcass was transferred to the NMML-32 freezer on the evening of 17 May.



Figure 24 – Right ventrolateral photograph of porpoise 03NWR05019 at time of initial discovery (17 May 2003) (Photo: S. Berta).

Gross Findings

A 138 cm total length, 37.5 kg immature female harbor porpoise was presented dead, 24 July 2003, in moderate body and poor post mortem condition (Figure 25). The porpoise was moderately well fleshed. In the right eye, the aqueous humor was diffusely dark red and translucent and a small amount of dark red fluid oozed from the ventral conjunctiva on manipulation of the head. The left eye was absent and the conjunctiva was eroded and irregular (post mortem scavenging). At the level of the right commissure, there was a moderate amount of periosteal edema and congestion of the mandibular body. Sand and debris were found in the nares. Throughout the ventrolateral aspect of the torso, there is extensive fissuring and loss of skin with only small remnants of intact epidermis evident. The left side of the carcass had extensive bird damage.



Figure 25 – Right lateral photograph of porpoise 03NWR05019 at time of necropsy (24 July 2003), demonstrating poor post mortem condition (Photo: B. Hanson).

Nervous system: In both the right and left inner ears, there were moderate peribullar accumulations of nematode parasites. Within the rostroventral region of the calverium, immediately below and elevating the periosteum, there was moderate accumulation of dark red subdural fluid.

Respiratory system: At the midlevel of the right lung lobe, moderately deep within the parenchyma, there was a 2x2 cm, pale tan yellow moderately firm nodule that eccentrically entrapped 2 dilated bronchioles; there was mild to moderate enlargement of the adjoining hilar lymph nodes which were pale grey brown and glistening on sectioned surface. Widely dispersed throughout the lung parenchyma, there were a moderate number of 1mm calcified parasite nodules.

Digestive system: Within the dorsomedial aspect of the hilar region of the liver as well as along the distal limit and to a much lesser extent, midlevel of the right liver lobe, immediately below and slightly elevating the liver capsule, there were small numbers of dilated biliary ductules with moderate numbers of trematode parasites interspersed within variable amounts of black mucoid deposits. There was minimal pancreatic periductular fibrosis and the mesenteric lymphatics were distended with chyme.

There were no apparent lesions within the hemolymphatic, cardiovascular, musculoskeletal, integumentary, urogenital or endocrine systems.

CT Findings

This animal was not scanned.

Gross Findings and Final Diagnoses

- 1). Lung: Bronchopneumonia, moderate, multifocal, granulomatous and eosinophilic, subacute with bronchiectasis and many nematode adults and larvae
- 2). Liver: Cholangiohepatitis, granulomatous and eosinophilic, mild, multifocal, with biliary ectasia and duct hyperplasia
- 3). Dura, base near cerebellum and left base of cranium: Congestion, moderate, diffuse.

4). Peribullar space: Hemorrhage, peri and retrobullar, mild with intralesional nematode parasites (Gross diagnosis)

Comments and Conclusions

Autolysis, freeze artifact and extensive post mortem scavenging prohibited gross evaluation of multiple tissues and hindered microscopic assessment of select tissues. Subdural and subarachnoid fluids were grossly noted in the brain. The cause of death of this animal was not determined. Due to the extent of post mortem decomposition, lesions consistent with acoustic trauma could not be excluded. The hepatic trematodiasis, colitis and verminous pneumonia were considered low grade and clinically insignificant. The bile duct parasites were most likely *Campula* spp and the lungworms were presumably *Halocercus* spp. Trace mineral analysis of the eye (vitreous humor) fluid revealed calcium levels of 8 mg/dl, magnesium of 10.4 mg/dl, phosphorus of 46 mg/dl and a blood urea nitrogen of 52.1 mg/dl. Although the BUN appeared elevated, the lack of established normal levels for healthy animals confounded interpretation of this data (Table 7). Bacterial culture of the spleen, lumbar lymph node, kidney and liver yielded light mixed growth of *Aeromonas hydrophila* and *Psychrobacter* spp and moderate to heavy growth of these isolates from the lung, brain and spinal cord. No *Salmonella* spp were recovered from the intestine and fungal culture of the lung were negative (Table 6). Based on the extent of post mortem change and lack of attendant inflammatory infiltrate, the heavy growth of *Clostridium perfringens* was attributed to post mortem proliferation. Fecal floatation and sedimentation were negative for parasites and there was no detectable domoic acid within ingesta as determined by SPE and analysis by HPLC.

PCR of pooled lung, lymph node, spleen and brain was negative for Morbillivirus and consensus *Brucella* spp and follow up viral culture on Mabin Darby and Vero cell lines was negative. Trace mineral and vitamin A analysis of the liver and kidney proved within normal reference limits (Table 7).

03NWR05012

History

This specimen was reported on the morning of 20 May 2003 floating off False Bay, San Juan Island (Figure 1), was collected by a whale watch boat operator before noon and delivered to Snug Harbor Marina. The specimen appeared to be in very fresh condition when first observed. Externally, there was no external evidence of net entanglement or trauma, except for bleeding from the left eye where birds had pecked away some of the tissue. The carcass was transported around noon to the UWFHL freezer (Figure 26). By mid-afternoon it was returned to the freezer at the Center for Whale Research due to insufficient space at the UWFHL freezer. The evening of 30 June 2003 it was taken to the NMML-4 freezer.

Gross Findings

A 123 cm total length, 30 kg immature male harbor porpoise was presented dead, 23 July 2003, in good nutritional and fair to moderate post mortem state (Figure 27). The animal was moderately well fleshed (Table 5). Within the dorsal aspect of the head, caudolateral



Figure 26 – Left lateral photograph of porpoise 03NWR05012 on day of initial report (20 May 2003) (Photo: Center for Whale Research).



Figure 27 – Left lateral photograph of porpoise 03NWR05012 at time of necropsy (23 July 2003) (Photo: B. Hanson).

margins of the nares, sub- and intermandibular skin, and bilaterally involving the mandibular fat pads, there was variably extensive congestion of the blubber and subjacent skeletal musculature. The melon was normal and the oral cavity was clear. There was no evidence of deep contusions associated with either mandible. The oropharyngeal mucosa was diffusely dark red. Immediately below the epiglottis and circumferentially involving the goose beak (larynx) mucosa, as well as extending along multiple contiguous laryngeal folds, there was moderate to marked submucosal congestion (Figure 28). Throughout the ventrolateral aspect of the mandible, there were scattered, superficial cutaneous aggregates of diatoms. Within the hypodermis of the perineum, there were multiple granulomas with parasitic tracts and intralesional nematodes. The left eye was punctured and collapsed. Along the distal limit of the right flipper, lower lip and mandible, there were scattered punctate ulcers frequently bound by red brown margins. There were multiple healed rake marks along the right ventral peduncle.

Nervous System: The inner surface of the calvarium was diffusely stained purple to red. There was a large amount of dark red fluid within the cranial cavity. A small amount of dark red fluid was below the meninges and the superficial aspect of the brain was suffused dark red. The dura and the border of bone at the posterior fossae had irregular borders. Both peribullar spaces had substantial burdens of parasites interspersed within

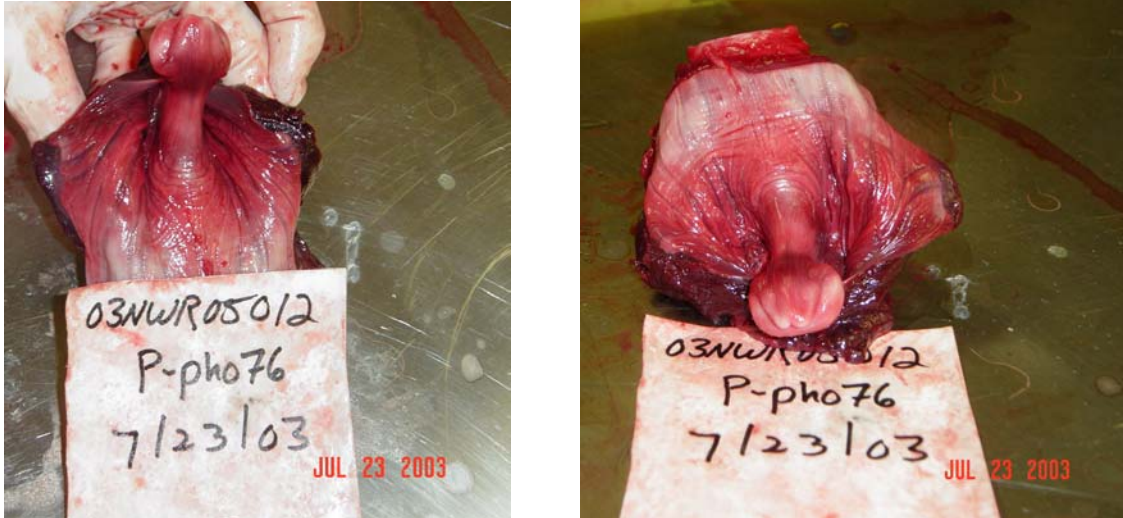

Figure 28 – Two photographs of the larynx of 03NWR05012 demonstrating localized submucosal congestion (Photos: D. Ketten).

moderate amounts of acute hemorrhage. Parasites were also present within the subtemporal region of the cranial vault. Along the lower left margin of the medulla oblongata and spinal cord at the levels of cervical vertebrae 1 and 2, the meninges were overlaid by a small amount of dark red gelatinous material (clot).

Respiratory System: The right lung was diffusely dark red. The left lung was mottled light pink with intervening, slightly depressed and mildly firmer dark red areas. A small amount of dark red froth was within the bronchi and trachea. There were rare 1mm, white, firm, parasitic aggregates widely dispersed throughout the pulmonary parenchyma.

Digestive System: Within the hilar region of the liver there were a small number of dilated bile ducts that contained multiple flukes interspersed within moderate amounts of dark black green tenacious material. There was a moderate amount of green brown ingesta throughout the intestines. A small number of nematodes overlaid or were interdigitated within the mucosa of the forestomachs. There was mild periductular fibrosis noted within the pancreas.

There were no significant lesions within the cardiovascular, musculoskeletal, urogenital, hemolymphatic or endocrine systems.

CT Findings

This animal was in moderate to poor condition. This was a young juvenile, based on size, relatively low skull mineralization and incompletely ossified cranial sutures.

Cranial soft tissues: A majority of the airways and associated spaces were compromised by fluid and foam deposits. The left sinus was opacified and contained both fluid and foam. The blubber layer was thin, but well-defined.

Intracranial/brain: A complex mass was bilaterally juxtaposed to the subtemporal entry

points of cranial nerves VII and VIII (Figure 29). The masses were irregularly shaped and most consistent with a mixture of fats and blood and degenerate parasite aggregates.

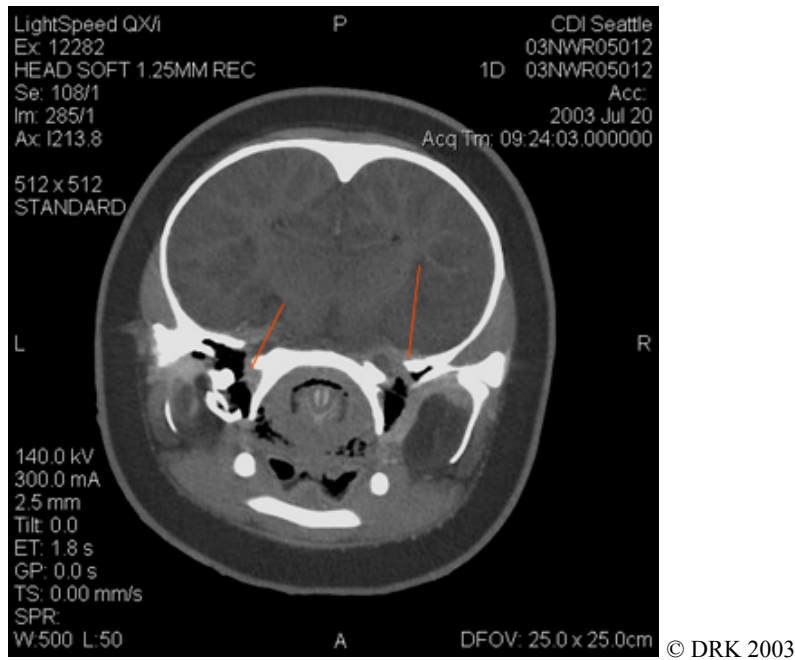


Figure 29 – A CT scan image of 03NWR05012 at the level of the subtemporal entry points of cranial nerves VII and VIII demonstrating a soft tissue mass juxtaposed to the entry points (orange arrows) (Image: D.R. Ketten).

Eyes: The right was normal. The left eye was collapsed with an associated, well-organized orbital clot.

Right ear: Aside from some moderate density masses in the medial peribullar region and middle ear, the right peribullar areas were normal. Although the middle ear structures were intact and normal, there were large soft tissue masses suggestive of nematode infestations. The inner ear was normal.

Left ear: The left peribullar areas, were normal with moderate density masses in the medial peribullar region and middle ear. The middle ear contained more soft tissue nematode aggregates than the right ear. The medial ear and inner ear structures were normal.

Post-cranial features: Both lungs were congested and atelectatic with the right more extensively affected at all levels than the left. A soft tissue deposit, with an inconsistent appearance suggestive of a mixture of foamy, sero-sanguinous material, extended from the larynx to the mid trachea.

Gross Findings and Final Diagnoses

- 1). Brain, meninges, ventral cerebral hemispheres and diencephalon: Congestion, moderate, diffuse
- 2). Skin, sub and inter-mandibular; adipose tissue, right upper mandible; spinal cord;

- pharynx; and larynx: Congestion, minimal to moderate, focally extensive
- 3). Ear, retro and peribullar: Hemorrhage, moderate, bilateral with florid intralesional nematode parasites (Gross diagnosis)
 - 4). Liver: Cholangiohepatitis, granulomatous and eosinophilic, focally extensive, moderate, with biliary ectasia, bile duct hyperplasia, periductular fibrosis and many trematodes
 - 5). Lung: Pneumonia, granulomatous and eosinophilic, multifocal, mild with few nematodes
 - 6). Skin, multiple sites: Granulomas, multiple with parasitic tracts and intralesional nematodes
 - 7). Skin, lip, mandible, and flippers: Ulcers, mild to moderate, multifocal (Gross diagnosis)
 - 8). Ear, peribullar (Gross diagnosis): Hemorrhage, moderate, focally extensive with intralesional nematode parasites.

Comments and Conclusions

Post mortem autolysis, freeze artifact and scavenging impeded gross evaluation of multiple organs and hindered microscopic assessment of selected tissues. The cause of death was not evident. No overt lesions consistent with acoustic trauma were observed. Pronounced congestion throughout the head and oropharyngeal mucosa was presumably due to dependent hypostasis. Based on measurements of blubber and axial skeletal muscle mass, this animal was considered moderately well fleshed (Table 5). The blood clot overlying the spinal cord was attributed to agonal or terminal thrashing at the time of stranding. The peribullar (presumptive *Stenurus* spp) and subcutaneous parasitism due to *Crassicauda* spp was more intense in this individual than examined cohorts. On CT image analysis, the most significant finding was intracranial parasitic invasion from the retrobullar regions through enlarged subtemporal apertures for the cranial nerves VII and VIII. The relatively low bone density of the cranium and incomplete cranial sutures are consistent with an immature animal. The burden of lungworms (presumptive *Halocercus* spp) and liver flukes (*Campula* spp) were not considered pathologically significant. Sections of skin disclosed superficial phytoplankton morphologically consistent with *Navicula* spp. Diatoms have previously been reported in north Pacific porpoises and are generally considered incidental findings (Holmes *et al.*, 1993). Although the precise cause of the cutaneous ulcers was unknown, agonal scavenging was a prime consideration. Aerobic bacterial culture yielded light mixed growth of alpha *Streptococcus* spp and nonhemolytic *Escherichia coli* from the lung and kidney with light growth of alpha *Streptococcus* spp from the mediastinal lymph node. A few colonies of *E. coli* were isolated from the spinal cord and there were no bacteria recovered from the liver or spleen (Table 6). Fungal culture of the lung was negative and no *Salmonella* spp were isolated from the small intestine. The heavy growth of *Clostridium perfringens* was attributed to post mortem proliferation. The extent of autolysis suggested that the remaining isolates were due to post mortem overgrowth. Fecal floatation and sedimentation were negative for parasites. Tissue culture of pooled lung, lymph node and spleen on Mabin Darby and Vero cell lines was negative and PCR for Morbillivirus and *Brucella* spp was unremarkable. Negative staining electron microscopy of the conjunctiva and cutaneous ulcers failed to reveal any discernible pathogens. Ingesta was

processed by strong anion exchange (SAX) solid phase extraction (SPE) cartridges followed by analysis by HPLC with UV detection at 242 nm and was negative for domoic acid. Trace mineral analysis of the liver and kidney were within normal reference limits and interpretation of the eye calcium (5.3 mg/dl), magnesium (5.24 mg/dl), phosphorus (40 mg/dl) and blood urea nitrogen (mg/dl) values is hindered due to the lack of established normal values; in cattle adequate or normal values are calcium: 6.0-7.5 mg/dl, magnesium: 1.90 mg/dl and phosphorus 1.3-3.0 mg/dl (Table 7).

03NWR06005

History

This porpoise was found stranded and collected at 20:00 hr on 2 June 2003 (Figure 30) at Long Beach (Figure 1) and delivered to the NMML-32 freezer on 3 June 2003.



Figure 30 – Right lateral photograph of 03NWR06005 at stranding site (2 June 2003) (Photo: Cascadia Research Collective).



Figure 31 – Right lateral photograph of porpoise 03NWR06005 at time of necropsy (21 July 2003) (Photo: B. Hanson).

Gross Findings

An adult 146 cm total length, 39 kg reproductively quiescent male harbor porpoise was presented dead, 21 July 2003, in poor body and moderate post mortem condition (Figure 31). There were minimal visceral and scant nuchal adipose stores and the animal was poorly muscled. Rostral to the melon and randomly within the subcutaneous tissue along

the entire length of the torso, there were extensive parasitic tracks, granulomas and nematodes within the hypodermis and, occasionally along deep fascial planes. Throughout the left ventrolateral margin of the pharynx and along the lateral aspect of ribs 2-4 and the cranial third to one-half of the scapula there was multifocally extensive, acute subcutaneous edema and hemorrhage. There were no apparent contusions in the melon. A small amount of red fluid exuded from the oral cavity. There was a small abrasion on the lower mandibular tip.

Respiratory and hemolymphatic systems: At the midlevel of the left lung, deep in the parenchyma, there was a large, 8-10 cm diameter, pale tan yellow moderately firm nodule which peripherally entrapped a small number of markedly ectatic bronchioles that were occluded by dense aggregates of nematode parasites. Within more normal adjoining parenchyma, there were multiple bronchioles and bronchi that contained variable numbers of nematodes. There was marked enlargement of the regional (mediastinal, hilar and pleural) lymph nodes that on sectioned surface were pale tan yellow, firm, and glistening. Large numbers of nematodes were located within the lumen of the trachea, larynx and nares. There was no foam or blood within the lumen of the nares.

Digestive system: Within the nonglandular compartment of the stomach, there were multiple proliferative and superficially ulcerative nodules and randomly throughout the glandular compartment, there were a small number of punctuate, erosions and ulcerations and trematodes. The small intestine was diffusely inflated with gas and multifocally contained a moderate amount of dark green black, particulate to fluid ingesta. Along the entire length of the large intestine, there was marked smooth muscle hypertrophy and attendant stenosis of the colonic lumen. Within the hilar region of the liver, there were multiple bile ducts that were moderately dilated by trematode parasites and dark green black tenacious material. Pronounced tooth wear was evident throughout the upper and lower arcades.

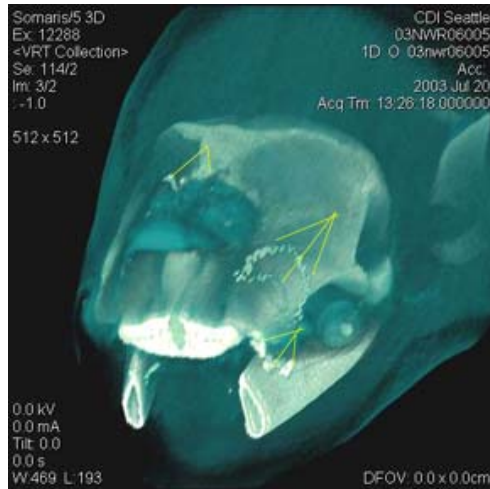
Nervous system: Bilaterally, within the medial and dorsal peribullar region, there were massive accumulations of nematode parasites (estimate 700 each). Diffusely, the surface of the brain was dark red black and there was variable congestion of the meningeal vasculature.

There were no apparent lesions within the cardiovascular, endocrine, urogenital or musculoskeletal systems.

CT Findings

Cranial soft tissues: The head was intact with normal soft tissue configurations. On the left side there was a convoluted, calcified nematode track that extended nearly 120 mm (Figure 32). There were numerous fibrotic or heavily calcified nodules in almost every major tissue suite of the head. There were substantial cystic deposits in the peri-esophageal tissues as well.

Intracranial/brain: The cranial structures were unremarkable.

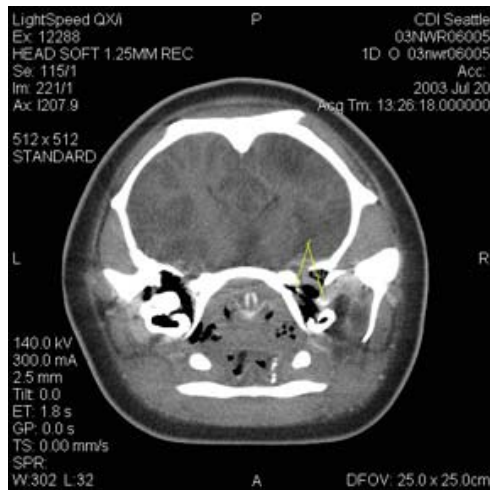


© DRK 2003

Figure 32 – A three-dimensional reconstruction of the head of 03NWR06005 demonstrating the outer surface of the head (blue) with the underlying skull and contoured, calcified parasitic inclusions (white patches with yellow arrows indicating major deposits) (Illustration: D.R. Ketten).

Eyes: Both eyes were intact.

Ears: Bilaterally, there was extensive parasitism with substantial calcified inclusions in the peribullar and middle ear tissues (Figure 33). The epithelium of the medial wall of the left retrobullar space was distended. The inner ears were normal bilaterally.

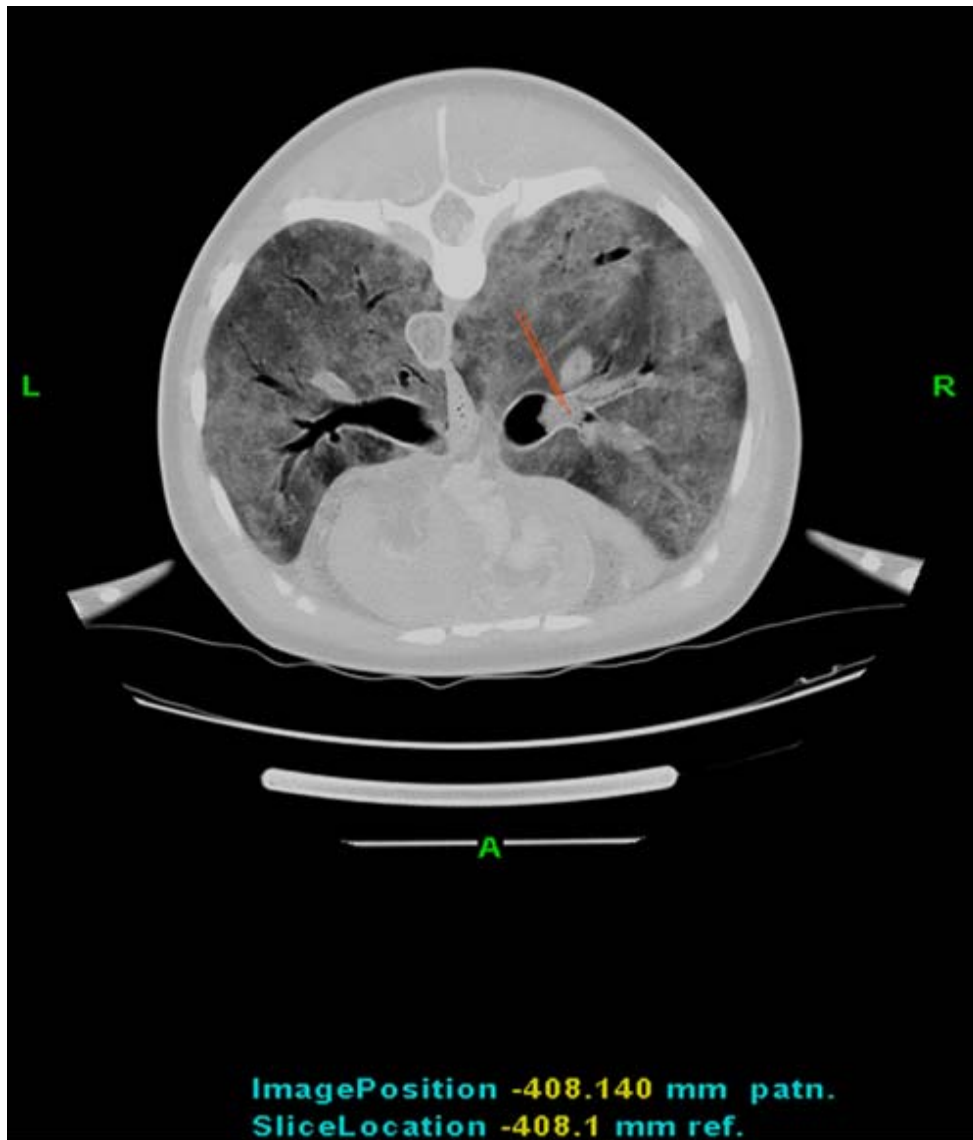


© DRK 2003

Figure 33 – A CT scan image of 03NWR06005 at the level of the peribullar spaces demonstrating a peribullar mass (yellow arrows) with inclusions similar to those seen in Figure 32, as well as calcified cysts in the esophagus (Image: D.R. Ketten).

Post-cranial features: The most remarkable features were extensive calcified parasitic tracts affecting most tissues. There were long, convoluted, calcified threads, several millimeters in diameter distributed throughout the blubber and musculature of the abdomen. The kidneys were well-defined and contained para-sagittal fibrotic masses.

The lungs had extensive clouding bilaterally that paralleled the bronchial tree. This process was more apparent and extensive in the left lung. The right lung airways contained foamy exudate and pooled fluid that extended to the larynx (Figure 34).



© DRK 2003

Figure 34 – A CT scan image of 03NWR06005 at the level of the lungs demonstrating an accumulation of foamy exudate (orange arrows) and pooled fluid that extended into the larynx (Image: D.R. Ketten).

Dorsal to the right bronchus of the middle lung lobe, there was a mass effect. Discrete opacified lesions were dispersed throughout both lungs.

Gross Findings and Final Diagnoses

- 1). Carcass: Emaciation, marked, generalized (Gross diagnosis).

- 2). Lung: Bronchopneumonia, severe, multifocal, granulomatous and eosinophilic, necrotizing, with bronchiectasis and massive bronchiolar and alveolar accumulation of nematode parasites with florid intralesional fungal hyphae
- 3). Lymph nodes, mediastinal, hilar and pleural: Lymphadenitis, subacute, multifocal, mild with lymphoid hyperplasia
- 4). Ear, peribullar: Hemorrhage, marked, focally extensive, with massive accumulation of parasitic nematodes (Gross diagnosis)
- 5). Colon, smooth muscle: Hypertrophy, marked, segmental, with submucosal edema and chronic colitis
- 6). Skin, generalized: Cellulitis and dermatitis, moderate to marked, multifocal, random, granulomatous chronic with mineral deposition and nematode parasites
- 7). Liver: Cholangiohepatitis, moderate, multifocal to coalescing, chronic with biliary ductular hyperplasia, ectasia, periductular fibrosis and intraluminal trematodes

Comments and Conclusions

Postmortem autolysis and freeze artifact hampered histopathology. The most significant lesions were extensive parasitic and mycotic bronchopneumonia, generalized emaciation (Table 5) and colonic smooth muscle hypertrophy. These lesions were profound and cumulatively would have resulted in significant antemortem morbidity and the death of this animal. No overt lesions associated with acoustic trauma were noted. CT image analysis confirmed the extensive calcified parasites particularly within the blubber, fascial planes, retrobullar regions, kidneys, biliary tree, and lungs. Based on experience with previous strandings, this parasitism was considered exceptional, even for this species of odontocetes in which parasites are commonly found. In marine mammals, pulmonary mycotic infections are typically associated with either localized immunosuppression or generalized debility (Reidarson *et al*, 2001). In this case, the emaciation and other disease processes may have been contributory factors. The fungal infection was likely acquired by inhalation of aerosolized conidia and there was no apparent extrapulmonary fungal involvement within the examined tissues. The lung parasites were likely *Halocercus* spp. The regional lymphadenitis and lymphoid hyperplasia were sequelae to the pneumonia. Histopathology of the grossly thickened segments of large intestine disclosed pronounced hypertrophy of the muscularis with variable accumulation of edema fluid and scattered foci of chronic inflammation within the overlying mucosa. Similar changes along varying levels of the small intestine has been reported in a number of animal species and has been associated with impactions, strictures, stenosis, adhesions, tumors or spastic contractions. In this porpoise, there were no apparent predisposing lesions, consequently the hypertrophic change was considered idiopathic. The intensity and distribution of the hypodermal (presumptive *Crassicauda* spp), gastrointestinal (*Anisakis* spp) and peribullar (likely *Stenurus* spp) parasites was enhanced in this relative to other stranded animals and may be secondary to profound debilitation. Fecal floatation and sedimentation were negative for parasites. The subcutaneous edema and hemorrhage noted within the thoracic region was likely due to localized agonal or terminal trauma (blunt impact). Urinalysis disclosed a specific gravity of 1.012, pH of 6.0 and protein of 300. Cytology of the urine disclosed abundant numbers of transitional epithelia, scattered crystal fragments, and small numbers of

leukocytes and extracellular cocci. The red and white blood cell count ranged from 0-1 per high-powered field and there was a large amount of amorphous debris. Trace mineral analysis was within normal in house reference limits and there was profound depletion of liver, vitamin A levels (Table 7). Due to the extent of emaciation, this may have represented dietary deficiency, although post mortem deterioration and loss could not be discounted. Vitamin A has been cited as a marker for immune function, and it is interesting to speculate that reduced levels may have been a factor in the pulmonary mycosis in this animal. PCR on pooled lung, lymph node, spleen and brain was negative for consensus and marine mammal variant *Brucella* spp and Morbillivirus and positive for Mollicutes, including *Ureaplasma* spp and *Mycoplasma* spp. At present, the contribution of these bacteria to antemortem morbidity in marine mammals is unknown. No viruses were isolated on Vero or Mabin Darby cell lines and negative staining electron microscopy of the conjunctiva was unremarkable. The light mixed growth of *Raoultella terrigena* and *Moraxella* spp from multiple internal viscera was not considered pathologically significant and there was no growth from the abdominal fluid, vent or atrioventricular valve (Table 6). The lack of significant fungi isolation from the lung may have been due to reduced viability associated with freezing and thawing of the tissues. No *Salmonella* spp were isolated from the small intestine and the heavy growth of *Clostridium perfringens* was attributed to post mortem proliferation. Ingesta was processed by SAX solid phase extraction cartridges followed by analysis by HPLC with UV detection at 242 nm and was negative for domoic acid. Interpretation of the eye calcium (5.8 mg/dl), magnesium (4.94 mg/dl), phosphorus (51 mg/dl) and blood urea nitrogen (59.8 mg/dl) values was hindered due to the lack of established normal values, in cattle adequate or normal values are calcium: 6.0-7.5 mg/dl, magnesium: 1.90 mg/dl and phosphorus 1.3-3.0 mg/dl with BUN serum values between 9-16 mg/dl (Table 7).

SUMMARY OF POST MORTEM EXAMINATIONS AND LABORATORY RESULTS

Pathology

Freeze artifact and moderate to advanced post mortem decomposition in five of the 11 animals significantly hindered pathologic and forensic evaluation of tissues for acoustic trauma as well as other disease processes. In addition, four of these animals had variably extensive percutaneous or deep muscle scavenge lesions. In three of five poorly preserved porpoises, significant diagnoses included salmonella septicemia (03NWR05006), fibrinous peritonitis (03NWR05008) and occipital fractures (03NWR05010). In better preserved animals, there was a single case of peri-mortem cranial fractures (03NWR05011) and one case of necrotizing pneumonia (03NWR06005). No significant findings were identified in the five remaining necropsied porpoises (03NWR05003 was scanned but not necropsied).

Within virtually all examined heads, there was diffuse dark red discoloration of the internal surface of the skull and surface of the brain with scattered submeningeal accumulation of dark red black fluid (as seen in Figure 5). Close evaluation of multiple sections of brain and periosteum failed to reveal any lesions consistent with acute hemorrhage; the grossly noted discoloration and accumulation of dark red fluid was not

associated with acute hemorrhage and most likely due to liquefactive and autolytic changes. Along the dorsolateral aspect and occasionally circumferentially investing the cranial cervical spinal cord and basioccipital region of the hindbrain, there was variable accumulation of either acute hemorrhage or hematoma formation (in 03NWR05001, 03NWR05005, 03NWR05008, 03NWR05011 and 03NWR05012) (Appendix F). Acute retrobullar and peribullar hemorrhage frequently mixed with moderate and more rarely, marked accumulations of nematode parasites were noted in eight of ten necropsied animals (03NWR05001, 03NWR05005, 03NWR05008, 03NWR05010, 03NWR05011, 03NWR05012, 03NWR05019 and 03NWR06005). With the exceptions of 03NWR05012, in which parasites were disproportionately heavy and extended into the calverium, and in case 03NWR06005, parasitic infections were considered within normal limits for wild porpoises (Appendix F).

Definitive signs consistent with more commonly observed human-related mortality such as fishery related injuries, gunshot, or ingestion of marine debris were not found in any of the animals examined.

CT Scans

Image analysis was conducted on seven intact carcasses and a single decapitated head (Table 8). Post mortem decomposition ranged from moderate to advanced with many tissues exhibiting freeze-thaw artifact. In five of eight samples, the skull was intact with no significant lesions noted within the brain. The grossly noted traumas in cases 03NWR05010 and 03NWR05011 are consistent with CT findings. In case 03NWR05003, due to the lack of density change within the temporal and parietal regions of the brain, a penetrating bone fragment (shard) that was reported on CT was considered a post mortem phenomenon. In case 03NWR05012, comparative low bone density and incompletely ossified cranial sutures were attributed to immaturity, rather than malnutrition or other disease processes. In this animal, there was pronounced enlargement of cranial nerve VII and VIII apertures, which presumably facilitated intracranial parasitic invasion from the peribullar into the subtemporal regions. In six of eight pairs of ears examined, there was uni- and occasionally bilateral peribullar parasitism frequently invested with variable amounts of blood deposits, in case 03NWR06005 with middle ear involvement. The precise contribution of these parasitic burdens to stranding in more severely affected animals is unknown. In case 03NWR05005, 03NWR05011, and possibly 03NWR05007, the intracochlear hemorrhage appears to be independent of peribullar parasitism and most likely reflects a sequel to trauma or some other entity and may be an artifact of postmortem migration and pooling. With the exception of case 03NWR05003 and 03NWR05007, the acousto-vestibular and facial nerves were intact and well defined. The etiopathogenesis of the degenerative changes noted in these two cases is unknown. The middle ears of virtually all the examined heads appeared normal with discrete middle ear spaces, intact ossicles, round and oval windows, and well defined normally distributed corpus cavernosum.

Body Composition

Detailed morphometric analysis and comparison with established reference values (McLellan *et al*, 2002) revealed that five of six animals analyzed (03NWR05001,

03NWR05005, 03NWR05008, 03NWR05011, and 03NWR05012) were within normal body condition and one animal (03NWR06005) was severely emaciated. Mild emaciation or mild cachexia was noted in 03NWR05008 and 03NWR05001. Extensive post mortem scavenging precluded body composition assessment in the remaining four animals; minimum estimates of total body mass were determined and are listed in Table 5.

Trace Mineral and Vitamin A analysis

Trace mineral and vitamin A analysis of liver and kidney, with the exception of select samples, proved within normal limits. Marginal increased liver magnesium were noted in three animals (03NWR05001, 03NWR05008, and 03NWR05011). These increased levels were not considered pathologically significant and increased calcium values in two porpoises (03NWR05005 and 03NWR05007) were considered secondary to dystrophic mineralization associated with the hepatobiliary trematodiasis. There was moderate reduction in liver vitamin A levels in one sample (03NWR05001), with no detectable levels in two additional animals (03NWR05005 and 03NWR06005). Due to the extent of post mortem change, it is difficult to resolve whether these reduced values represent post mortem degradation or hypovitaminosis A. Although there were no microscopic lesions consistent with vitamin A deficiency, the possibility of reduced levels and impaired immune function, particularly in case 03NWR06005, cannot be entirely discounted.

Parasitology

Parasites have been implicated in strandings of several species of cetaceans, particularly where infection affected the ears, brain or auditory nerves, or was so overwhelming that an animal developed severe pneumonia or enteritis (Geraci and St. Aubin, 1987; Morimitsu *et al.*, 1987). Although fecal floatation and sedimentation were unremarkable within each of the examined porpoises, histopathology confirmed the verminous pneumonia and biliary trematodiasis in all 10 examined carcasses, subcutaneous nematodiasis in four of 10 (03NWR05007, 03NWR05008, 03NWR05012 and 03NWR06005) and gastrointestinal helminthiasis in four of 10 porpoises (03NWR05005, 03NWR05006, 03NWR05012 and 03NWR06005). The relative intensity and distribution of gastrointestinal parasites in this case series was consistent with previous studies. The trematodes noted within the stomach of 03NWR05007 likely originated from the hepatobiliary tree and were refluxed from the duodenum. The lack of discernible ova or parasites within ingesta may be due to intermittent shedding, post mortem decomposition or some other factor(s). The peribullar (presumptive *Stenurus* spp) and subcutaneous parasitism due to *Crassicauda* spp in 03NWR05012 was more intense in this individual than examined cohorts. The intensity and distribution of the hypodermal (presumptive *Crassicauda* spp), gastrointestinal (*Anisakis* spp) and peribullar (likely *Stenurus* spp) parasites was enhanced in 03NWR06005 relative to other stranded animals and may be secondary to profound debilitation. The cutaneous diatoms noted in 03NWR05007 and 03NWR05012 were considered incidental findings of limited pathologic significance.

Virology and Ancillary Molecular Studies

Pooled lung, lymph node, spleen and brain were evaluated for dolphin morbillivirus by PCR and all cases were negative. Tissue culture on Mabin Darby and Vero cell lines failed to reveal any cytopathic effect in all 10 cases. In select cases, negative staining electron microscopy of conjunctival and oral mucosal scrapes failed to reveal any virus like particles. Aspirates of the epididymal abscess in case 03NWR05008 were negative by PCR for marine mammal variant and universal *Brucella* spp and the intralesional parasitic ova were considered significant. In case 03NWR06005, cerebrospinal fluid had a titer of 1:16 for canine distemper by virus neutralization. Due to the extent of blood contamination and hemolysis, this result was interpreted as a false positive. Follow up PCR for canine distemper was negative and immunohistochemistry of representative lung sections for Morbillivirus were unremarkable. This case was positive by PCR for Mollicutes, which are considered secondary to impaired respiratory defenses associated with the profound necrotizing pneumonia.

Bacteriology

Aerobic culture from multiple internal viscera of all 10 porpoises yielded pure to mixed, variable growth of 16 different species of bacteria with three cases that had no bacterial growth from select tissues (Table 6). Due to the lack of attendant inflammatory infiltrate, the *Clostridium perfringens* isolates from each of the 10 animals is attributed to post mortem overgrowth, and the most significant growth was the *Salmonella Newport* Group C2, from case 03NWR05006. *Escherichia coli* (non-hemolytic) was isolated from five cases, and alpha *Streptococcus* spp from four.

Blubber Analysis

Blubber samples were collected from eight animals (Appendix G). Percent lipid values ranged from 44-83%, which are similar to those reported previously for blubber of harbor porpoise stranded off the west coast of the U.S. (Calambokidis and Barlow, 1991). Concentrations of POPs were comparable to levels previously reported in West Coast harbor porpoise (Calambokidis and Barlow, 1991; Jarman *et al.*, 1996), and were much lower than those reported in presumably “healthy” harbor porpoise incidentally caught in a gill-net fishery off the northwest Atlantic coast (Tilbury *et al.*, 1997). The concentration of POPs in the harbor porpoise in this investigation were also significantly lower than that of a Southern Resident killer whale that stranded in Long Beach, Washington in April 2002 (NOAA Fisheries/Northwest Fisheries Science Center, Environmental Conservation Division, unpub. data).

Stomach Prey Preliminary Analysis

Six of 10 examined stomachs lacked ingesta. Only scant fish bones, otoliths and squid beaks were identified in those animals with gastric contents. No freshly consumed prey or prey tissue remains were present in any of the stomachs. A cursory examination of the otoliths and squid beaks during the preliminary sorting process revealed common prey items such as Pacific whiting or Pollock (*Theragra chalcogramma*), herring (*Clupea harengus pallasi*), sanddab (*Citharichthys sordidus*), an as yet unidentified sculpin (Cottidae) and market squid (Cephalopoda). No unusual prey remains were encountered, and the large number of empty stomachs and absence of freshly consumed prey is typical

of findings over the last five years for evaluation of the stomach contents of stranded porpoises from the Pacific Northwest (W. Walker, pers comm.).

Pending Analyses

Detailed analysis of prey species and age determination from extracted teeth will be completed at the National Marine Mammal Laboratory, Seattle, Washington.

DISCUSSION

Intensive post mortem examination and ancillary testing of 11 harbor porpoises that stranded between 2 May and 2 June 2003 did not reveal any definitive signs of acoustic trauma that could be associated with the 5 May 2003 active mid-range tactical sonar system used by the *USS SHOUP*. Over 70 percent of the porpoises examined were graded by the team as moderate to advanced post mortem decomposition at the time of necropsy. A presumptive or definitive cause of death could be determined for five of 11 animals examined (Appendix F). Of these five animals, there were two cases of agonal or perimortem blunt force trauma, a single case of fibrinous peritonitis, one porpoise with salmonellosis, and one with a profound necrotizing pneumonia. The examinations did not reveal any definitive signs of acoustic trauma in any of the porpoises examined. The multidisciplinary team noted that lesions consistent with acoustic trauma can be difficult to interpret or obscured, especially in animals in advanced post mortem decomposition.

Although, to the best of our knowledge, lesions associated with acoustic trauma have not been previously documented in harbor porpoise, sonar related strandings and pathology has been observed in other species. In March 2000, a multispecies mass stranding of 17 cetaceans (*Ziphius cavirostris*, *Mesoplodon densirostris*, *Balaenoptera acutorostrata*, *Stenella frontalis*) was discovered in the Bahamas (U.S. Department of Commerce and Secretary of the Navy, 2001). During the Bahamas event, stranded animals were found up to 36 hours after naval sonar deployment with most animals reported as live beachings within 12 hours of the ship's transit. Seven of the animals were known to have died and ten animals were returned to the water alive. In contrast, there were no live strandings of Washington porpoises, and animals were recovered sporadically throughout the entire month. From an epidemiologic perspective, the sample size is too small and biased to infer a specific relationship with respect to sonar usage and subsequent strandings.

The May 2003 increase in harbor porpoise strandings may be coincidental, biased by increased reporting efforts, and/or unrelated to sonar use. Observations of the May 5 sonar activities were highly publicized which could have resulted in increased awareness and reporting of porpoise strandings. In addition to recordings made on May 5, hydrophone operators submitted audio files of sounds, they identified as sonar, dated 9 December 2002, 24 April 2003 and 4 May 2003. NOAA Fisheries also received video footage labeled "porpoises and Navy Sonar 25 April 03". There was, however, no attendant increase in observed strandings or recovered carcasses associated with the April or December dates. This could be biased by less intensive carcass monitoring and recovery efforts or other unknown factors. Prior to any publicity, the Stranding Network, as part of its usual activities, was engaged in recovering stranded porpoises. Four of the

porpoises examined for cause of death in this investigation were recovered prior to 5 May, three on 5 and 6 May and the remaining seven during the subsequent weeks.

Determining the cause of death in an animal can be affected by various factors including carcass decomposition, handling, transport, and lack of clear or consistent gross or microscopic findings, as well as the lack of validated (standardized) species specific diagnostic assays. In previous strandings associated with sonar, significant gross findings included acute hemorrhage within the inner ear, subarachnoid space, and lateral ventricles (U.S. Department of Commerce and Secretary of the Navy, 2001). In a recent case report of stranded cetaceans in the Canary Islands, multisystemic intravascular microcavitations and emphysema formation were consistently observed (Jepson *et al.*, 2003). In the porpoise investigation, the pathologies that were consistently identified within the examined harbor porpoises were related to post mortem change, freezing artifact, or were not considered sufficiently severe to account for the loss of these animals. Although seven porpoises were assigned a condition code of 2 (fresh) at time of initial observation, by the time the animals were collected, stored and then necropsied, most carcasses had undergone significant post mortem decomposition (Table 1).

Overlying the basi-occipital and cranial cervical regions of the spinal cord of five porpoises, as well as involving the retrobullar and peribullar spaces of seven individuals in this investigation, there was variable degrees of hemorrhage, with some hematoma formation (03NWR05001, 03NWR05005, 03NWR05008, 03NWR05011, 03NWR05012). Although these anatomic regions may be considered predilection sites for acoustic-related injury, in this case series, the hemorrhage and hematoma formation were most consistent with agonal thrashing associated with stranding, or intralesional nematode parasites. There was no consistent evidence of retrobullar, extra-ocular (two of eight examined animals), nor ventricular hemorrhage in the brain. Based on histopathology, the grossly noted submeningeal dark red fluid was considered unassociated with acute hemorrhage and more likely represented post mortem and cyclic freeze-thaw artifact. In one of nine animals, circumferentially involving the sub-epiglottic mucosa, there was moderate submucosal congestion with variable extravascular accumulation of proteinaceous material. Additional recuts and special stains failed to conclusively demonstrate hemoglobin and due to the extent of post mortem change, the precise nature of this material is unknown.

In this investigation, due to the number of people involved in responding to, collecting, transporting and thawing the carcasses, it was not possible to maintain a standardized approach to track body position or orientation during each of these procedures. Further, individual animals were stored in freezers of different types including frost-free freezers, which have freeze-thaw cycles, that were also considered a potential source for free blood or hemorrhagic artifact. Therefore, definitive differentiation amongst congestion, hypostasis, and red staining of tissues found during necropsy examinations (antemortem versus perimortem injury or post mortem dependent pooling) was hindered. The reddened tissue discoloration observed in all the animals was considered to be related to a combination of freezer artifact and autolytic (liquefactive) change.

In animals that present with no historical information or prior clinical evaluation and in advanced stages of autolysis, the precise cause of death cannot always be determined. Over the course of the last 4-5 years, a precise cause of death has not been determined in approximately 50% of necropsied animals from southern British Columbia and northern Washington State (S. Raverty, pers. comm.). Post mortem decomposition or insufficient time from the initial insult to development of histologically or grossly definitive lesions may hamper precise determination of a cause of death. Due to the state of decomposition and the very nature of strandings which provide only snapshots of information in the life of an animal, comprehensive biological data on all important factors and acute or chronic disease state in any of these animals was not available.

CONCLUSION

No common cause for the increased number of harbor porpoise strandings observed in Washington State 2 May – 2 June 2003 was found. A presumptive cause of death was determined for five of 11 harbor porpoises that were examined. Lesions consistent with or diagnostic for acoustic trauma were not identified in any of the 11 porpoises that were examined. The multidisciplinary team noted that lesions consistent with acoustic trauma can be difficult to interpret or obscured, especially in animals in advanced post mortem decomposition. The possibility of acoustic trauma as a contributory factor in the mortality of the porpoises examined could not be ruled out. Very little is known about acoustic trauma as a mortality factor in cetaceans and further investigation into its pathogenesis and impact is warranted. Furthermore, efforts to support the prompt and systematic search and recovery of stranded marine mammal carcasses in the region may benefit future such investigations, should they occur.

LITERATURE CITED

- Calambokidis, J. and Barlow, J. 1991. Chlorinated hydrocarbon concentrations and their use for describing population discreteness in harbor porpoises in Washington, Oregon, and California. In: Marine mammal strandings in the United States. Reynolds III, J.E. and Odell, D.K. (Eds.). Proceedings of the Second Marine Mammal Stranding Workshop, 3-5 December 1987, Miami, FL, pp. 101-110. U.S. Dep. Commerc., NOAA Tech. Rep. 98.
- Calambokidis, J., Steiger, G.H., and J.C. Cubbage. 1987. Marine mammals in the southwestern Strait of Juan de Fuca: natural history and potential impacts of harbor development in Neah Bay. Final report prepared by Cascadia Research Collective, Olympia, WA, for the Seattle District, Army Corps of Engineers, Seattle, WA, Contract No. DACW67-85-M-0046, 103 p.
- Calambokidis, J., Osmek, S., and Laake, J.L. 1997. Survey report for the 1997 aerial surveys for harbor porpoise and other marine mammals of Oregon, Washington, and British Columbia outside waters. Cascadia Research Collective, Olympia, Washington, USA. 36pp.
- Calle, P.P., Stetter, M.D., Cook, R.A., McClave, C.A., and Massucci, S. 1995. Enteric salmonellosis of captive Pacific walrus (*Odobenus rosmarus divergens*), in *Proceedings of the 26th Annual Workshop of the International Association of Aquatic Animal Medicine*, 92-93.
- Foster, G., Patterson, I.A., and Munro, D.S. 1999. Monophasic group B Salmonella species infecting harbour porpoises (*Phocoena phocoena*) inhabiting Scottish coastal waters. *Veterinary Microbiology* 65(3):227-231.
- Geraci, J.R. and St. Aubin, D.J. 1987. Effects of parasites on marine mammals. *International Journal for Parasitology* 17:407-414.
- Geraci, J.R. and Lounsbury, V.J. 1993. Specimen and data collection. Pp. 175-228 in *Marine Mammals Ashore: A Field Guide for Strandings*, Geraci, J.R. and Lounsbury, V.J. (Eds.). Texas A&M Sea Grant Program, Galveston. 305pp.
- Holmes, R.W., Nagasawa, S and Takano, H. 1993. The morphology and geographic distribution of epidermal diatoms of the Dall's porpoise (*Phocoenoides dalli*) in the northern Pacific ocean. *Bulletin of the National Science Museum, Tokyo, Series B* 19(1):1-18.
- Jarman, W.M., Norstrom, R.J., Muir, D.C.G., Rosenberg, B., Simon, M. and Baird, R.W. 1996. Levels of organochlorine compounds, including PCDDs and PCDFs, in the blubber of cetaceans from the West Coast of North America. *Marine Pollution Bulletin* 32:426-436.

- Jepson, P.D., Arbelo, M., Deaville, R., Patterson, I.A.P., Castro, P., Baker, J.R., Degollada, E., Ross, H.M., Herráez, P., Pocknell, A.M., Rodríguez, F., Howie, F.E., Espinosa, A., Reid, R.J., Jaber, J.R., Martin, V., Cunningham, A.A. and Fernández, A. 2003. Gas-bubble lesions in stranded cetaceans. *Nature* 425: 575.
- McLellan, W.A., Koopman, H.N., Rommel, S.A., Read, A.J., Potter, C.W., Westgate, A.J. and Pabst, D.A. 2002. Ontogenetic allometry and body composition of harbour porpoises (*Phocoena phocoena*, L.) from the western North Atlantic. *Journal of Zoology, London* 257(4):457-472.
- Morimitsu, T., Nagai, T., Ide, M., Kawano, H., Naichuu, A., Koono, M. and Ishii, A. 1987. Mass stranding of odontocete caused by parasitogenic eight cranial neuropathy. *Journal of Wildlife Diseases* 23:586-590.
- Pascual, S., Abollo, E. and Lopez, A. 2000. Elemental analysis of cetacean skull lesions associated with nematode infections. *Dis. Aquat. Organisms* 42:71-75.
- Raga, J., Aznar, F., Balbuena, J. and Fernandez, M. 2002. Parasites. Pp 867-876 in *Encyclopedia of marine mammals*, first edition, Perrin, W.F., Würsig, B. and Thewissen, J.G. (Eds.). Academic Press, San Diego, CA. 1414 pp.
- Reidarson, T.H., McBain, J.F., Dalton, L.M. and Rinaldi, M.G. 2001. Mycotic diseases. Pp. 337-355 in *Handbook of marine mammal diseases*, second edition, Dierauf, L.A. and Gulland, F.M.D. (Eds.). CRC Press, Boca Raton, FL. 1063 pp.
- Schroeder, R.J., Delli Ouadre, C.A., McIntyre, R.W., and Walker, W.A. 1973. Marine mammal disease surveillance program in Los Angeles County. *Journal of the American Veterinary Medical Association* 163(6): 580-581.
- Sloan, C.A., Brown, D.W., Pearce, R.W., Boyer, R.H., Bolton, J.L., Burrows, D.G., Herman, D.P. and Krahn, M.M. In preparation. Determining aromatic hydrocarbons in sediments and tissues using accelerated solvent extraction and gas chromatography/mass spectrometry. In: *Aquatic Toxicology-Volume 2*, Ostrander, G.K. (Ed.). CRC Press, Boca Raton, FL.
- Smith, W.A., Mazet, J.A. and Hirsh, D.C. 2002. Salmonella in California wildlife species: prevalence in rehabilitation centers and characterization of isolates. *Journal of Zoo and Wildlife Medicine* 33(3):228-235
- Thornton, S.M., Nolan, S. and Gulland, F.M.D. 1998. Bacterial isolates from California sea lions (*Zalophus californianus*), harbor seals (*Phoca vitulina*) and northern elephant seals (*Mirounga angustirostris*) admitted to a rehabilitation center along the central California coast. *Journal of Zoo and Wildlife Medicine* 29:171-176.

Tilbury, K.L., Stein, J.E., Meador, J.P., Krone, C.A. and Chan, S.-L. 1997. Chemical contaminants in harbor porpoise (*Phocoena phocoena*) from the north Atlantic coast: tissue concentrations and intra- and inter-organ distribution. *Chemosphere* 34(9/10):2159-2181.

United State Department of Commerce and the Secretary of the Navy. 2001. Joint Interim Report: Bahamas Marine Mammal Stranding Event of 15-16 March 2000. 59 pp.

GLOSSARY

Agonal: Occurring at the moment of or just before death.

Antemortem: Before death.

Anterior: Situated in front of or in the forward part of an organ, toward the head end of the body.

Atelectasis: The collapse of part or all of a lung by blockage of the air passages (bronchus or bronchioles), or by very shallow breathing.

Autolyzed: Enzymatic, bacterial or self-digestion of cells or tissues after death.

Avulsed: Torn off from.

Basioccipital: Pertaining to the back of the skull or head.

Commensal: Living in a state of commensalism which is a relation between two kinds of organisms in which one obtains food or other benefits from the other without damaging or benefiting it.

Comminuted: Reduced to small particles.

Computerized tomography: The creation of an image displaying anatomic information, created by a computer synthesis of x-ray transmission data obtained in several different directions in a given plane.

Congestion: Excessive or abnormal accumulation of fluid (e.g., blood) in a tissue or organ.

Contusion: An injury of a part without a break in the skin; a bruise.

Diffuse: Widely distributed.

Dura mater: The outermost (and toughest) of the three membranes (meninges) covering the brain and spinal cord.

Ectatic: Distended or dilated.

Edema: An abnormal infiltration and excess accumulation of serous fluid in connective tissue.

Erythema: Abnormal redness of the skin due to vascular congestion and hyperemia.

Etiology: The cause(s) or origin of a disease.

Extravasation: A discharge or escape, as of blood, from a vessel into the tissues.

Fascia: A band or sheet of fibrous tissue deep to the skin.

Florid: In full bloom; occurring in fully developed form.

Fibrosis: The formation of a scar.

Gross findings: Observations of organs and tissues that are visible to the naked eye.

Hemorrhage: The escape of blood from the vessels (often associated with an organized clot). The effect of hemorrhage depends on the rate, volume and location of the bleeding.

Histological findings: The branch of anatomy that deals with the minute structure, composition, and function of these tissues (histopathological findings: the histology of diseased tissues).

Hypostasis: The gravitational settling of blood in the dependent parts of an organ or body.

Imbibe: Absorb a liquid (such as blood).

Inferior: Situated below, or directed downward; used in reference to the lower surface of an organ or structure.

Inguinal: Of, relating to, or found in the groin.

Lesion: Wound, injury, or pathological change in a tissue.

Lividity: Discoloration of dependent parts due to the gravitation of blood.

Morbidity: Condition of being diseased or sick.

Morphology: The science of the form and structure of organisms, organs and tissues.

Necrosis: The sum of the morphological changes indicative of cell degeneration and death and caused by a complex disruption and progression of subcellular processes. It may affect groups of cells or part of a structure or an organ.

Parenchyma: The functional elements of an organ (as distinguished from its framework, or stroma).

Pathology: The branch of science concerned with all aspects of disease, especially the essential nature of disease, with special reference to the structural and functional changes in tissues and organs of the body which cause or are caused by disease.

Per os: By mouth.

Peribullar: Around the bullae, the tissues and space surrounding the bony housing of the ear.

Perimortem: Around the time of death.

Peritonitis: Refers to inflammation of the peritoneum, a membrane that covers the surfaces of both the organs that lie in the abdominal cavity and the inner surface of the abdominal cavity itself.

Perivascular: Situated around a vessel.

Petechial: Characterized by pinpoint, nonraised, well delineated, purplish red spots caused by intradermal or submucosal bleeding.

Pia mater: The innermost of the three membranes (meninges) covering the brain and spinal cord.

Post mortem: After death.

Posterior: Situated in back of, or in the back part of, or affecting the back part of a structure.

Pulmonary: Pertaining to the lungs.

Purulent: Containing, consisting of, or being pus.

Sequela: An consequence of disease or injury.

Serosa: An enclosing thin membrane.

Significant finding: Any pathologic finding that is considered not normal for that tissue, organ, or specimen.

Subcutaneous: Beneath the skin (includes the epidermis and dermis [blubber]).

Superior: Situated above, or directed upward.

Vitreous humor: Fluid contained within the eye.

Figure 1. – Reported porpoise strandings in Washington State 2 May – 2 June 2003
(Courtesy of B. Hanson).

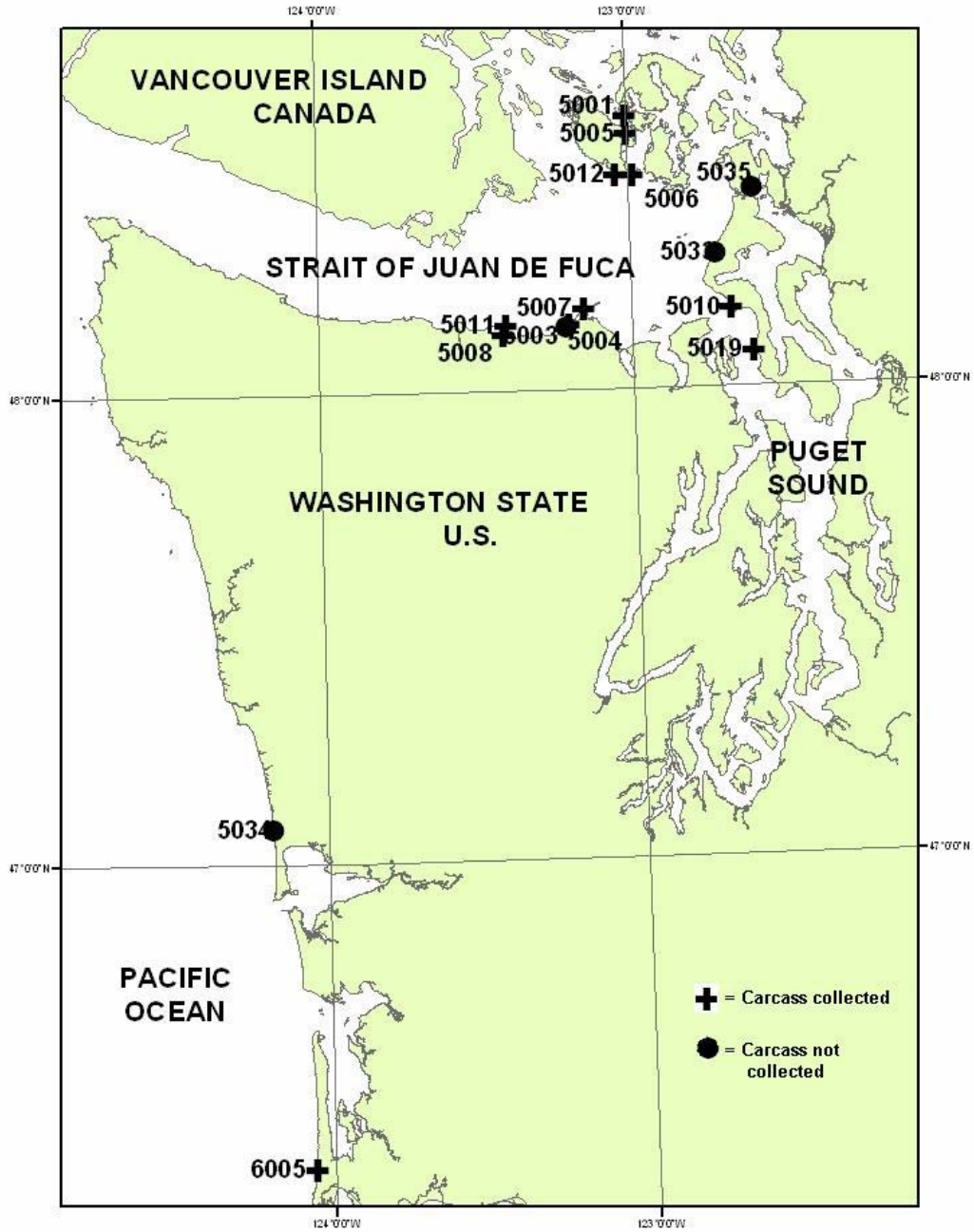


Table 1. Reported harbor porpoise stranding events in Washington State - 2 May - 2 June 2003.

Date of initial observation	Location	County	Initial carcass condition	Field ID	Registration number	Sex	Date collected	CT Scan 7/20/03	Necropsy date	Carcass condition code at necropsy	Cause of death
5/2/2003	Neck Point, Shaw Island	San Juan	2	2003-SJ006	03NWR05001	F	5/2/2003	yes	7/23/2003	3	Not determined
5/4/2003	County Park, Dungeness Spit	Clallam	4	DNG-03-002	03NWR05003	F	05/08/03 head & fetus collected	yes	N/E	4+	N/E
5/4/2003	County Park, Dungeness Spit	Clallam	4	N/E	03NWR05004	U	not collected	no	N/E	N/E	N/E
5/4/2003	Jackson Beach, San Juan Island	San Juan	3	2003-SJ007	03NWR05005	F	5/5/2003	no	7/24/2003	3	Not determined
5/5/2003	South Beach, San Juan Island	San Juan	3	2003-SJ008	03NWR05006	F	5/5/2003	yes	7/23/2003	3	Salmonella septicemia
5/6/2003	Dungeness Spit	Clallam	2	DNG-03-001	03NWR05007	F	5/6/2003	yes	7/22/2003	2+	Not determined
5/6/2003	Ennis Creek, Discovery Trail	Clallam	3	OCNMS03Pp01	03NWR05008	M	5/6/2003	yes	7/23/03-head; 7/24/03-body	4	Not determined (peritonitis maybe contributory)
5/12/2003	West Beach, Whidbey Island	Island	unknown	N/E	03NWR05033	U	not collected	no	N/E	N/E	N/E
5/12/2003	Ocean City	Grays Harbor	3	N/E	03NWR05034	U	not collected	no	N/E	N/E	N/E
5/13/2003	Admiralty Head, Whidbey Island	Island	2	WIC051303SD	03NWR05010	M	5/13/2003	no	7/24/2003	3+	Not determined (likely occipital base fracture)
5/16/2003	Ediz Hook, Port Angeles	Clallam	2	OCNMS03Pp02	03NWR05011	F	5/16/2003	yes	7/23/2003	3	Cranial fractures
5/17/2003	Lagoon Point, Whidbey Island	Island	2	WIE051703SB	03NWR05019	F	5/17/2003	no	7/23/2003	3	Not determined
5/20/2003	Eagle Point, San Juan Island	San Juan	2	2003-SJ009	03NWR05012	M	5/20/2003	yes	7/23/2003	2	Not determined
6/2/2003	Long Beach	Pacific	2	CRC-490	03NWR06005	M	6/2/2003	yes	7/22/2003	2	Bronchopneumonia

2 = fresh

3 = moderate decomposition

4 = advanced decomposition

Table 2. Spatial distribution of harbor porpoise stranding events in Washington State for all months of the year (1992 - June 2003).

<u>Year</u>	<u>Inland waters</u>	<u>Outer coast</u>	<u>Totals</u>
1992	2	8	10
1993	6	2	8
1994	4	0	4
1995	5	0	5
1996	0	0	0
1997	2	0	2
1998	5	0	5
1999	2	0	2
2000	4	2	6
2001	14	1	15
2002	9	0	9
<u>Totals</u>	53	13	66
2003 (thru June 30)	12	3	15

Table 3. Harbor porpoise stranding events in Washington State 1992-2003 (April - June).

<u>Year</u>	<u>April</u>	<u>May</u>	<u>June</u>	<u>Total</u>		<u>Total number events for year</u>	<u>Percent of annual stranding</u>
1992	0	2	0	2		10	20
1993	1	2	1	4		8	50
1994	0	1	0	1		4	25
1995	2	0	0	2		5	40
1996	0	0	0	0		0	0
1997	0	1	0	1		2	50
1998	2	0	0	2		5	40
1999	0	1	0	1		2	50
2000	1	0	0	1		6	17
2001	1	7	0	8		15	53
2002	1	2	2	5		9	56
<u>Totals</u>	8	16	3	27		66	41
2003	1	13	1	15		15	-

Table 4. Freezer types and specifications used to store and transport harbor porpoise carcasses prior to necropsy.

Manufacturer/Model	Type (top-load/chest vs. walk-in)	Location	Cycle type	Carcass Number(s)
Kalt Thermoguard	Walk-in	NOAA/National Marine Mammal Lab (Building 4)	Frost-free (-20 - 0 F)	03NWR05012
Horeco (model unknown)	Walk-in	NOAA/National Marine Mammal Lab (Building 32)	Frost-free	All specimens
Kenmore 11233	Top-load	University of Washington/Friday Harbor Laboratory	Manual defrost	03NWR05001 03NWR05005 03NWR05006
Kenmore (model unknown)	Top-load	Center for Whale Research	Manual defrost	03NWR05012
Kenmore 13551	Top-load	NOAA/Office of Protected Resources	Manual defrost	03NWR05001 03NWR05003 03NWR05006 03NWR05007 03NWR05008 03NWR05011 03NWR05012 03NWR06005
Kenmore 67519231796	Top-load	USFWS/Dungeness National Wildlife Refuge	Manual defrost	03NWR05007

Table 5. Body composition of harbor porpoises (*Phocoena phocoena*) examined during necropsy session. Comparative "normal" data are from Atlantic harbor porpoises presented in McLellan *et al.* (2002).

ID #	Sex	TL (cm)	TBM (kg)	Blubber mass (kg)	"Normal" blubber mass (kg)	Blubber /TBM (%)	"Normal" blubber /TBM (%)	Axial muscle mass (kg)	"Normal" axial muscle mass (kg)	Axial muscle /TBM (%)	"Normal" axial muscle /TBM (%)	Notes
03NMR05001	F	136	39*	N/E	10.88 +/- 1.17	CBD	29.47 +/- 3.16	7.39	8.44 +/- 1.94	CBD	21.65 +/- 2.41	Scavenger damage limited blubber and % analyses Axial muscle mass within normal range
03NWR05005	F	126	33.5*	13.59	10.88 +/- 1.18	CBD	29.47 +/- 3.17	6.44	8.44 +/- 1.95	CBD	21.65 +/- 2.41	Blubber mass higher than normal Axial muscle mass slightly below normal range
03NWR05006	F	152	48.5*	N/E		CDB		N/E		CBD		Severe decomposition and scavenger damage
03NWR05007	F	145.5	38.5*	N/E				7.56	**8.44 +/- 1.95			**This animal is longer than the normal sample in McLellan <i>et al.</i> 2002
03NWR05008	M	146	N/E	N/E	12.79 +/- 1.69	CBD	24.69 +/- 2.46	N/E	11.54 +/- 1.76	CBD	24.59 +/- 2.03	Severe decomposition
03NWR05010	M	154	N/E	N/E		CBD		N/E		CBD		Severe decomposition and scavenger damage
03NWR05011	F	136.5	37*	12.72	10.88 +/- 1.18	CBD	29.47 +/- 3.17	6.70	8.44 +/- 1.95	CBD	21.65 +/- 2.41	Scavenger damage limited % analyses Blubber mass higher than normal Axial muscle mass within normal range
03NWR05019	F	138	37.5*	N/E		CBD		N/E		CBD		Decomposition and scavenger damage
03NWR05012	M	123	30	9.15	10.00 +/- 1.70	29.7	29.62 +/- 2.04	5.36	6.98 +/- 1.19	17.9	20.06 +/- 2.04	Total mass of this specimen slightly below that of normal range for immature males (34.7 +/- 4.5 kg) Blubber within normal range Axial muscle below normal range
03NWR06005	M	146	39	8.98	12.79 +/- 1.69	23.03	24.69 +/- 2.46	8.08	11.54 +/- 1.76	20.71	24.59 +/- 2.03	Total mass of this specimen below that of normal range for mature males (47.1 +/- 4.9 kg) Blubber mass, axial muscle mass and Axial muscle/TBM(%) below normal range

If scavenger damage precluded collecting blubber and/or axial mass on both sides, reported values represent 2 times the value for a single side. Blubber and axial muscles are bilaterally symmetric (McLellan *et al.* 2002).

* = Minimum estimate of total body mass (TBM) due to tissue loss or carcass decomposition.

TL = Total length

CBD = Could not be determined

Table 6. Bacteriology results for harbor porpoise specimens

Bacteria Isolated	03NWR05001	03NWR05005	03NWR05006	03NWR05007
<i>Acinetobacter sp.</i>			kidney, thymus, mesenteric l.n.	
<i>Actinetobacter johnsonii</i>	thymus, thoracic fluid			
<i>Aeromonas hydrophila</i>		spleen, thymus, lung, spinal cord, liver, hilar l.n., mediastinal l.n.		
<i>Clostridium perfringens</i>	small intestine	intestine	small intestine	small intestine
<i>Enterobacter sp.</i>		spleen, thymus, spinal cord, liver, hilar l.n., mediastinal l.n.		brain, mammary gland, spleen, spinal cord, thymus, hemothorax, mesenteric l.n., lung
<i>Enterococcus sp.</i>				
<i>Eschericia coli - non hemolytic</i>	small intestine, thymus, spleen, kidney, liver, mesenteric l.n.			
<i>Moraxella sp.</i>				
<i>Proteus sp.</i>	mesenteric l.n.			
<i>Pseudomonas sp.</i>	small intestine, thymus, spleen, mediastinal l.n., lung, mestenteric l.n., spinal cord	spleen, liver, hilar l.n.		
<i>Pseudonas flourescens</i>				lung
<i>Psychrobacter sp.</i>				
<i>Raoultella terrigena</i>				
<i>Salmonella newport Group C2</i>			Hilar l.n., kidney, lung, spleen, liver, thymus, mesenteric l.n., small intestine	
<i>Streptococcus (non-hemolytic)</i>				mammary milk
<i>Streptococcus sp.(alpha)</i>	small intestine	intestine		
no bacteria isolated		kdiney, urine		

l.n. = lymph node

Table 6. Bacteriology results for harbor porpoise specimens

Bacteria Isolated	03NWR05008	03NWR05010	03NWR05011
<i>Acinetobacter sp.</i>			
<i>Actinetobacter johnsonii</i>			
<i>Aeromonas hydrophila</i>		liver, kidney, mesenteric l.n., lung, brain, spleen	
<i>Clostridium perfringens</i>	small intestine	small intestine	small intestine, colon
<i>Enterobacter sp.</i>	lungs, spleen, mesenteric l.n., epididymis abscess		
<i>Enterococcus sp.</i>		liver, kidney, mesenteric l.n., lung, brain, spleen, small intestine	liver, thymus, spleen, mesenteric l.n., urine, kidney, lung, spinal cord
<i>Eschericia coli - non hemolytic</i>	kidney, lungs, mesenteric l.n.	liver, kidney, mesenteric l.n., lung, brain, spleen, small intestine	kidney, lung, spinal cord, small intestine, colon
<i>Moraxella sp.</i>			
<i>Proteus sp.</i>			
<i>Pseudomonas sp.</i>			
<i>Pseudonas flourescens</i>			
<i>Psychrobacter sp.</i>			
<i>Raoultella terrigena</i>			
<i>Salmonella newport Group C2</i>			
<i>Streptococcus (non-hemolytic)</i>	liver		
<i>Streptococcus sp.(alpha)</i>	kidney, lungs, spleen, mesenteric l.n., epididymis abscess, small intestine		
no bacteria isolated			

l.n. = lymph node

Table 6. Bacteriology results for harbor porpoise specimens

Bacteria Isolated	03NWR05019	03NWR05012	03NWR06005
<i>Acinetobacter sp.</i>			
<i>Actinetobacter johnsonii</i>			
<i>Aeromonas hydrophila</i>	spleen, lumbar l.n., kidney, liver, brain, spinal cord, lung, pericolic l.n., small intestine		
<i>Clostridium perfringens</i>	small intestine	small intestine	large intestine
<i>Enterobacter sp.</i>			
<i>Enterococcus sp.</i>			
<i>Eschericia coli - non hemolytic</i>		spinal cord, lung, kidney, small intestine	
<i>Moraxella sp.</i>			prescapular l.n., brain, kidney, spleen
<i>Proteus sp.</i>			
<i>Pseudomonas sp.</i>			
<i>Pseudonas flourescens</i>			
<i>Psychrobacter sp.</i>	spleen, lumbar l.n., kidney, liver, brain, spinal cord, lung, pericolic l.n., small intestine		
<i>Raoultella terrigena</i>			liver, prescapular l.n., brain, mesenteric l.n., spleen, lung, liver swab, kidney
<i>Salmonella newport Group C2</i>			
<i>Streptococcus (non-hemolytic)</i>			
<i>Streptococcus sp.(alpha)</i>		mediastinal l.n., lung, kidney	
no bacteria isolated		liver, spleen	abdominal fluid

l.n. = lymph node

Table 7. Trace mineral and Vitamin A analyses of liver, kidney and vitreous humor

	03NWR 05001	03NWR 05005	03NWR 05006	03NWR 05007	03NWR 05008	03NWR 05010	03NWR 05011	03NWR 05012	03NWR 05019	03NWR 06005		Reference range (Porpoise and dolphin)	
LIVER													
Se (ppm)	2.98	1.99	1.6	4.24	12.43	5.93	2.11	2.92	3.19	10.56		0.90-38.0	
Cu (ppm)	8	5	8	6.3	10.2	5.9	9	12	12.6	12.9		4.0-60.0	
Zn (ppm)	59	25	40	27	36	47	62	41	56	84		22-120	
Fe (ppm)	307	221	212	230	261	278	210	225	228	236		130-300	
Mn (ppm)	5.8	3.8	4.6	3.5	5.7	5	6.5	4.9	4.8	5.5		1.0-10.0	
Pb (ppm)	<2	<2	<2	<2	<2	<2	<2	<2	<2	<2		<1.0	
Cd (ppm)	0.2	<0.2	<0.2	<0.2	0.3	0.3	<0.2	<0.2	<0.2	0.6		<0.1-12.0	
Ca (ppm)	92	314	49	302	78	96	133	65	39	46		38-200	
Mg (ppm)	330	166	192	203	410	511	260	219	194	210		130-280	
Vit A (mcg/g)	120	51	714	340	355	1011	520	800	298	<5		250-3000	
Retinol (mcg/g)	82	35	457	219	172	710	318	419	186	<3			
Retinol palmitate (mcg/g)	46	16	256	120	183	301	202	381	112	<3			
KIDNEY													
Cu (ppm)	3.3	4.1	4	5.9	4.8	4.1	4.2	6.2	5.3	3.8		3.0-7.9	
Zn (ppm)	24	27	26	26	25	28	28	29	26	25		16-44	
Fe (ppm)	146	115	158	112	215	151	123	106	159	69		90-150	
Mn (ppm)	1.5	1.5	1.7	1.6	2.5	1.4	1.5	1.5	1.6	1.6		1.0-3.0	
Pb (ppm)	<2	<2	<2	<2	<2	<2	<2	<2	<2	<2		<1.0	
Cd (ppm)	0.5	0.2	0.6	0.5	1.1	0.9	0.2	0.5	0.4	2.4		0.08-72.0	
Ca (ppm)	154	79	179	148	323	98	167	134	127	160		60-150	
Mg (ppm)	371	152	251	193	351	137	193	170	280	185		120-240	
VITREOUS												Reference range (cattle)	
Ca (mg/dl)		8.8		6.4		7.7		5.3	8	5.8			6.0-7.5
Mg (mg/dl)		10.32		7.04		20.79		5.24	10.4	4.94			1.9
P (mg/dl)		37		72		64		40	46	51		1.9-2.7	1.3-3.0
BUN (mg/dl)		54.5		73.9		57		113.4	52.1	59.8			9-16(serum)

Bold type indicates value(s) outside of reference range.

Table 8. Summary of CT scan analysis

Anatomic Site	Case Number	
	03NWR05001	03NWR05003
Ears		
Peribullar regions		
left	extensive parasitism and good pneumatization	aerated and normal
right	clot formation and good pneumatization	aerated and normal
Internal Auditory Canal		
left	well defined and intact	canals normal
right	well defined and intact	canals normal
Acouto-Vestibular/ Fascial Nerve		
left	intact and well defined	partially degenerate nerves
right	intact and well defined	partially degenerate nerves
Middle ear		
left	no significant findings, distinct middle ear spaces and well defined corpus cavernosum	aerated, retracted corpus cavernosum, intact ossicles, round and oval windows
right	no significant findings, distinct middle ear spaces and well defined corpus cavernosum	aerated, retracted coprus cavernosum, intact ossicles, round and oval windows
Inner ear		
left	canals symmetric and normal	symmetric and apparently normal canals
right	canals symmetric and normal	symmetric and apparently normal canals

Table 8. Summary of CT scan analysis

Anatomic Site	Case Number	
	03NWR05006	03NWR05007
Ears		
Peribullar regions		
left	well aerated and normal	clear and well aerated, well defined suspensory ligament
right	dorsal retrobullar space, extensive hemorrhage	clear and well aerated, well defined suspensory ligament
Internal Auditory Canal		
left	no evidence of hemorrhage or parasitism, left tympanic bone partially demineralized	no evidence of blood or abnormal material
right	intact and well defined canal	no evidence of blood or abnormal material
Acousto-Vestibular/ Fascial Nerve		
left	internal auditory canal well defined	intact, but in some sections, degenerative change evident
right	intact and well defined	intact, but in some sections, degenerative change evident
Middle ear		
left	normal with distinct middle ear space and well defined corpus cavernosum, round and oval windows normal	distinct air spaces, well defined corpus cavernosum, normal ossicles and round windows
right	normal with distinct middle ear space and well defined corpus cavernosum	distinct air spaces, well defined corpus cavernosum, normal ossicles and round windows
Inner ear		
left	no significant findings	canals symmetric and normal, possible intracochlear blood
right	no significant findings	canals symmetric and normal, possible intracochlear blood

Table 8. Summary of CT scan analysis

Anatomic Site		Case Number		
	03NWR05008	03NWR05011	03NWR05012	03NWR06005
Ears				
Peribullar regions				
left	generally clear, well aerated, substantial parasitism	two masses (organized clot and moderate parasitism) and bone fractures	intact, moderate density parasitic masses and no other significant findings	extensive parasitism
right	generally clear, well aerated, moderate parasitism	no significant findings	intact and no significant findings	extensive parasitism
Internal Auditory Canal				
left	normal and unremarkable	no significant findings	intact and no significant findings	no significant findings
right	normal and unremarkable	no significant findings	intact and no significant findings	no significant findings
Acousto-Vestibular/ Fascial Nerve				
left	normal	no significant findings	intact and no significant findings	no significant findings
right	normal	no significant findings	intact and no significant findings	no significant findings
Middle ear				
left	clearly delineated air spaces and well defined corpus cavernosum	no significant findings	intact and no significant findings	extensive parasitism
right	clearly delineated air spaces and well defined corpus cavernosum	no significant findings	intact and no significant findings	extensive parasitism
Inner ear				
left	symmetric and normal, normal intracochlear fluid	in apical and middle turns, blood	normal, no evidence of blood or other intracochlear abnormalities	no significant findings
right	symmetric and normal, normal intracochlear fluid	in apical and middle turns, blood	normal, no evidence of blood or other intracochlear abnormalities	no significant findings

Table 9: Concentrations of selected persistent organic pollutants measured in blubber of harbor porpoise that stranded at various sites in Washington State, May - June 2003.

Registration number	Sex	Age Length class [†] (cm)	Condition of carcass	Percent lipid	ng/g, wet weight					ng/g, lipid weight					
					β-HCH	HCB	ΣCHLDS	ΣDDTs	ΣPCBs	β-HCH	HCB	ΣCHLDS	ΣDDTs	ΣPCBs	
03NWR05005	Female	mmature	126	Mod. dec.§	74	400	430	1,200	5,600	5,900	540	580	1,600	7,600	8,000
03NWR05001	Female	mmature	136	Fresh	68	190	190	560	2,300	2,600	280	280	820	3,400	3,800
03NWR05011	Female	mmature	137	Fresh	75	240	210	640	3,100	3,000	320	280	850	4,100	4,000
03NWR05019	Female	mmature	138	Fresh	75	230	270	670	2,700	3,700	310	360	890	3,600	3,600
03NWR05006	Female	mmature	152	Mod. dec.§	83	270	280	730	3,400	3,400	330	340	880	4,100	4,100
03NWR05007	Female	mmature	146	Fresh	70	330	330	980	4,400	5,800	470	470	1,400	6,300	8,300
03NWR05012	Male	mmature	123	Fresh	69	310	250	880	3,800	4,500	450	360	1,300	5,500	6,500
<i>Overall immature mean ± SE</i>						<i>280 ± 29</i>	<i>280 ± 33</i>	<i>810 ± 92</i>	<i>,600 ± 460</i>	<i>,100 ± 540</i>	<i>390 ± 41</i>	<i>380 ± 44</i>	<i>,100 ± 130</i>	<i>,900 ± 640</i>	<i>,500 ± 850</i>
03NWR06005	Male	Adult	146	Fresh	44	250	39	1,200	5,700	6,800	570	89	2,700	13,000	15,000

¶Results of analyses from Environmental Conservation Division, NWFSC, NMFS, Seattle, WA

†Age class of each animal estimated from length data using information from Gearin PJ, Melin SR, DeLong RL, Kajimura H, Johnson MA (1994)

Harbor porpoise interactions with a chinook salmon set-net fishery in Washington State. Rep. Int. Whal. Comm. (Special Issue 15):427-438.

§Mod. dec. = moderately decomposed

Appendix A. – Level A Stranding forms

MARINE MAMMAL STRANDING REPORT - LEVEL A DATA

FIELD # _____ NMFS REGIONAL # _____ (NMFS USE) NATIONAL DATABASE# _____ (NMFS USE)

COMMON NAME: _____ GENUS: _____ SPECIES: _____

EXAMINER _____ Letterholder: _____

Name: _____ Affiliation: _____

Address: _____ Phone: _____

LOCATION State: _____ County: _____ City: _____ Locality Details: _____ _____ Latitude: _____ N Longitude: _____ W	OCCURRENCE DETAILS MS#: _____ (NMFS USE) Mass Stranding: <input type="checkbox"/> YES <input type="checkbox"/> NO # Animals: _____ Signs of Human Interaction: <input type="checkbox"/> YES <input type="checkbox"/> NO <input type="checkbox"/> Could not be Determined (CBD) (Check one or more) <input type="checkbox"/> 1. Boat Collision <input type="checkbox"/> 3. Fishery Interaction <input type="checkbox"/> 2. Shot <input type="checkbox"/> 4. Other Human Interaction: _____ How determined: <input type="checkbox"/> External Exam <input type="checkbox"/> Internal Exam <input type="checkbox"/> Not Examined Other Causes: <input type="checkbox"/> YES <input type="checkbox"/> NO <input type="checkbox"/> CBD Describe: _____																									
DATE OF INITIAL OBSERVATION Year: _____ Month: _____ Day: _____ STATUS (Check ONE) <input type="checkbox"/> 1. Alive <input type="checkbox"/> 4. Advanced Decomposition <input type="checkbox"/> 2. Fresh Dead <input type="checkbox"/> 5. Mummified/Skeletal <input type="checkbox"/> 3. Moderate Decomposition <input type="checkbox"/> 6. Dead - Condition Unknown		DATE OF EXAMINATION (LEVEL- A) <input type="checkbox"/> Not Able to Examine Year: _____ Month: _____ Day: _____ CONDITION (Check ONE) <input type="checkbox"/> 1. Alive <input type="checkbox"/> 4. Advanced Decomposition <input type="checkbox"/> 2. Fresh Dead <input type="checkbox"/> 5. Mummified/Skeletal <input type="checkbox"/> 3. Moderate Decomposition <input type="checkbox"/> 6. Dead - Condition Unknown																								
INITIAL LIVE ANIMAL DISPOSITION (Check one or more) <input type="checkbox"/> 1. Left at Site <input type="checkbox"/> 5. Euthanized at Site <input type="checkbox"/> 2. Immediate Release at Site <input type="checkbox"/> 6. Died at Site <input type="checkbox"/> 3. Relocated <input type="checkbox"/> 7. Transferred to Rehabilitation <input type="checkbox"/> 4. Disentangled <input type="checkbox"/> 8. Died during Transport <input type="checkbox"/> 9. Other	MORPHOLOGICAL DATA SEX (Check ONE) AGE CLASS (Check ONE) <input type="checkbox"/> 1. Male <input type="checkbox"/> 1. Adult <input type="checkbox"/> 4. Pup/Calf <input type="checkbox"/> 2. Female <input type="checkbox"/> 2. Subadult <input type="checkbox"/> 5. Unknown <input type="checkbox"/> 3. Unknown <input type="checkbox"/> 3. Yearling Straight Length: _____ <input type="checkbox"/> cm <input type="checkbox"/> in <input type="checkbox"/> actual <input type="checkbox"/> estimate Weight: _____ <input type="checkbox"/> kg <input type="checkbox"/> lb <input type="checkbox"/> actual <input type="checkbox"/> estimate PHOTOS/VIDEOS TAKEN: <input type="checkbox"/> YES <input type="checkbox"/> NO Disposition: _____																									
CONDITION (Check ONE) <input type="checkbox"/> 1. Sick <input type="checkbox"/> 3. Apparently Healthy <input type="checkbox"/> 5. Other <input type="checkbox"/> 2. Injured <input type="checkbox"/> 4. Out of Habitat Date: _____ Rehabilitation Facility: _____ Comments: _____	WHOLE CARCASS DISPOSAL (Check one or more) <input type="checkbox"/> 1. Left at site <input type="checkbox"/> 4. Rendered <input type="checkbox"/> 7. Unknown <input type="checkbox"/> 2. Buried <input type="checkbox"/> 5. Sunk <input type="checkbox"/> 3. Towed <input type="checkbox"/> 6. Frozen for Later Examination SPECIMEN DISPOSITION (Check one or more) <input type="checkbox"/> 1. Scientific collection <input type="checkbox"/> 2. Educational collection <input type="checkbox"/> 3. Other: _____ Comments: _____ NECROPSIED <input type="checkbox"/> YES <input type="checkbox"/> NO Date: _____ NECROPSIED BY: _____																									
TAG DATA <table style="width: 100%; border-collapse: collapse;"> <thead> <tr> <th style="text-align: left;">ID #</th> <th style="text-align: left;">Color</th> <th style="text-align: left;">Type</th> <th style="text-align: left;">* Placement</th> <th style="text-align: left;">Applied</th> <th style="text-align: left;">Present</th> </tr> </thead> <tbody> <tr> <td>_____</td> <td>_____</td> <td>_____</td> <td>(Circle ONE) D DF L LF LR RF RR</td> <td style="text-align: center;"><input type="checkbox"/></td> <td style="text-align: center;"><input type="checkbox"/></td> </tr> <tr> <td>_____</td> <td>_____</td> <td>_____</td> <td>D DF L LF LR RF RR</td> <td style="text-align: center;"><input type="checkbox"/></td> <td style="text-align: center;"><input type="checkbox"/></td> </tr> <tr> <td>_____</td> <td>_____</td> <td>_____</td> <td>D DF L LF LR RF RR</td> <td style="text-align: center;"><input type="checkbox"/></td> <td style="text-align: center;"><input type="checkbox"/></td> </tr> </tbody> </table> <p><small>* D = Dorsal; DF = Dorsal Fin; L = Lateral Body LF = Left Front; LR = Left Rear; RF = Right Front; RR = Right Rear</small></p>			ID #	Color	Type	* Placement	Applied	Present	_____	_____	_____	(Circle ONE) D DF L LF LR RF RR	<input type="checkbox"/>	<input type="checkbox"/>	_____	_____	_____	D DF L LF LR RF RR	<input type="checkbox"/>	<input type="checkbox"/>	_____	_____	_____	D DF L LF LR RF RR	<input type="checkbox"/>	<input type="checkbox"/>
ID #	Color	Type	* Placement	Applied	Present																					
_____	_____	_____	(Circle ONE) D DF L LF LR RF RR	<input type="checkbox"/>	<input type="checkbox"/>																					
_____	_____	_____	D DF L LF LR RF RR	<input type="checkbox"/>	<input type="checkbox"/>																					
_____	_____	_____	D DF L LF LR RF RR	<input type="checkbox"/>	<input type="checkbox"/>																					

MARINE MAMMAL STRANDING REPORT

NW-2003-1000774
SID#

(NMFS USE)

FIELD NO.: 2003-SJ006 NMFS REGISTRATION NO.: 03NW05001
 COMMON NAME: Harbor porpoise GENUS: Phocoena SPECIES: phocoena
 EXAMINER Name: _____ Agency: The Whale Museum Phone: _____
 Address: _____

TS 500
7120

LOCATION State: <u>WA</u> County: <u>San Juan</u> City: _____ Locality Details: <u>Floating off</u> <u>Neck Pt. Shaw</u> <u>Island</u> *Latitude: _____ N *Longitude: _____ W	TYPE OF OCCURRENCE Mass Stranding: <input type="checkbox"/> Yes <input checked="" type="checkbox"/> No # Animals _____ Human Interaction: <input type="checkbox"/> Yes <input type="checkbox"/> No <input checked="" type="checkbox"/> ? Check one: <input type="checkbox"/> 1. Boat Collision <input type="checkbox"/> 2. Shot <input type="checkbox"/> 3. Fishery Interaction <input type="checkbox"/> 4. Other _____ How determined: _____ Other Causes (if known): _____
--	---

DATE OF INITIAL OBSERVATION: Yr. <u>2003</u> Mo. <u>5</u> Day <u>2</u> CONDITION: Check one: <input type="checkbox"/> 1. Alive <input checked="" type="checkbox"/> 2. Fresh dead <input type="checkbox"/> 3. Moderate decomp. <input type="checkbox"/> 4. Advanced decomp. <input type="checkbox"/> 5. Mummified <input type="checkbox"/> 7. Unknown	DATE OF EXAMINATION: Yr. <u>2003</u> Mo. <u>5</u> Day <u>2</u> CONDITION: Check one: <input type="checkbox"/> 1. Alive <input checked="" type="checkbox"/> 2. Fresh dead <input type="checkbox"/> 3. Moderate decomp. <input type="checkbox"/> 4. Advanced decomp. <input type="checkbox"/> 5. Mummified <input type="checkbox"/> 7. Unknown
--	--

LIVE ANIMAL -- Condition and Disposition: Check one or more: <input type="checkbox"/> 1. Released at site <input type="checkbox"/> 2. Sick <input type="checkbox"/> 3. Injured <input type="checkbox"/> 4. Died <input type="checkbox"/> 5. Euthanized <input type="checkbox"/> 6. Rehabilitated and released <input type="checkbox"/> 7. Unknown Transported to: _____ <input type="checkbox"/> Died <input type="checkbox"/> Released Date: _____	TAGS APPLIED?: <input type="checkbox"/> Yes <input checked="" type="checkbox"/> No TAGS PRESENT?: <input type="checkbox"/> Yes <input checked="" type="checkbox"/> No <table style="width: 100%; border-collapse: collapse;"> <tr> <td style="width: 33%;"></td> <td style="width: 33%; text-align: center;">Dorsal</td> <td style="width: 33%; text-align: center;">Left</td> <td style="width: 33%; text-align: center;">Right</td> </tr> <tr> <td>Tag No.(s):</td> <td>_____</td> <td>_____</td> <td>_____</td> </tr> <tr> <td>Color(s):</td> <td>_____</td> <td>_____</td> <td>_____</td> </tr> <tr> <td>Type:</td> <td>_____</td> <td>_____</td> <td>_____</td> </tr> <tr> <td>Placement</td> <td></td> <td style="text-align: center;">Front/Rear</td> <td style="text-align: center;">Front/Rear</td> </tr> </table>		Dorsal	Left	Right	Tag No.(s):	_____	_____	_____	Color(s):	_____	_____	_____	Type:	_____	_____	_____	Placement		Front/Rear	Front/Rear
	Dorsal	Left	Right																		
Tag No.(s):	_____	_____	_____																		
Color(s):	_____	_____	_____																		
Type:	_____	_____	_____																		
Placement		Front/Rear	Front/Rear																		

CARCASS -- Disposition: Check one: <input type="checkbox"/> 1. Left at site <input type="checkbox"/> 2. Buried <input type="checkbox"/> 3. Towed <input checked="" type="checkbox"/> 4. Sci. collection: (see below) <input type="checkbox"/> 5. Edu. collection: (see below) <input type="checkbox"/> 6. Other _____ <input type="checkbox"/> 7. Unknown	MORPHOLOGICAL DATA: Sex -- Check one: <input type="checkbox"/> 1. Male <input checked="" type="checkbox"/> 2. Female <input type="checkbox"/> 7. Unknown Straight Length: _____ <input type="checkbox"/> cm <input type="checkbox"/> in <input type="checkbox"/> est *Weight _____ <input type="checkbox"/> kg <input type="checkbox"/> lb <input type="checkbox"/> est PHOTOS TAKEN? <input checked="" type="checkbox"/> Yes * <input type="checkbox"/> No * during necropsy
---	---

REMARKS: Collected for necropsy. Stored in ATL freezer

DISPOSITION OF TISSUE/SKELETAL MATERIAL: _____

6/23/03

MARINE MAMMAL STRANDING REPORT - LEVEL A DATA

To scan?
To rotten?

FIELD #: DN6-03-002 NMFS REGIONAL #: 03NWRO5003 NATIONAL DATABASE #: NW-2003-1000776

COMMON NAME: porpoise GENUS: _____ SPECIES: _____

EXAMINER: _____ Letterholder: _____

Name: _____ Affiliation: USFWS

Address: Port Angeles Phone: _____

LOCATION State: <u>WA</u> County: <u>Clallam</u> City: <u>Sequim</u> Locality Details: <u>1 mile S of Neumegness Spit</u> Latitude: <u>48° 08' 19.9" N</u> Longitude: <u>123° 11' 52.6" W</u>	OCCURRENCE DETAILS Mass Stranding: <input type="checkbox"/> YES <input checked="" type="checkbox"/> NO # Animals: _____ Signs of Human Interaction: <input type="checkbox"/> YES <input type="checkbox"/> NO <input checked="" type="checkbox"/> Could Not be Determined (CBD) (Check one or more) <input type="checkbox"/> 1. Boat Collision <input type="checkbox"/> 3. Fishery Interaction <input type="checkbox"/> 2. Shot <input type="checkbox"/> 4. Other Human Interaction: _____ How determined: <input type="checkbox"/> External Exam <input type="checkbox"/> Internal Exam <input type="checkbox"/> Not Examined Other Causes: <input type="checkbox"/> YES <input type="checkbox"/> NO <input type="checkbox"/> CBD Describe: _____
---	--

DATE OF INITIAL OBSERVATION Year: 2003 Month: 05 Day: 04 DATE OF EXAMINATION (LEVEL A) Not Able to Examine Year: 2003 Month: 05 Day: 08

STATUS (Check ONE) <input type="checkbox"/> 1. Alive <input type="checkbox"/> 4. Advanced Decomposition <input type="checkbox"/> 2. Fresh Dead <input type="checkbox"/> 5. Mummified/Skeletal <input checked="" type="checkbox"/> 3. Moderate Decomposition <input type="checkbox"/> 6. Dead - Condition Unknown	CONDITION (Check ONE) <input type="checkbox"/> 1. Alive <input checked="" type="checkbox"/> 4. Advanced Decomposition <input type="checkbox"/> 2. Fresh Dead <input type="checkbox"/> 5. Mummified/Skeletal <input type="checkbox"/> 3. Moderate Decomposition <input type="checkbox"/> 6. Dead - Condition Unknown
--	---

INITIAL LIVE ANIMAL DISPOSITION (Check one or more) <input type="checkbox"/> 1. Left at Site <input type="checkbox"/> 5. Euthanized at Site <input type="checkbox"/> 2. Immediate Release at Site <input type="checkbox"/> 6. Died at Site <input type="checkbox"/> 3. Relocated <input type="checkbox"/> 7. Transferred to Rehabilitation <input type="checkbox"/> 4. Disentangled <input type="checkbox"/> 8. Died During Transport <input type="checkbox"/> 9. Other	MORPHOLOGICAL DATA SEX (Check ONE) <input type="checkbox"/> 1. Male <input checked="" type="checkbox"/> 2. Female <input type="checkbox"/> 3. Unknown AGE CLASS (Check ONE) <input checked="" type="checkbox"/> 1. Adult <input type="checkbox"/> 4. Pup/Calf <input type="checkbox"/> 2. Subadult <input type="checkbox"/> 5. Unknown <input type="checkbox"/> 3. Yearling
---	--

CONDITION (Check ONE)
 1. Sick 3. Apparently Healthy 5. Other
 2. Injured 4. Out of Habitat

PHOTOS/VIDEOS TAKEN: YES NO ATTACHED

Disposition: _____

TAG DATA <table border="1" style="width: 100%; border-collapse: collapse;"> <thead> <tr> <th>ID#</th> <th>Color</th> <th>Type</th> <th>Placement (Circle One)</th> <th>Applied</th> <th>Present</th> </tr> </thead> <tbody> <tr> <td></td> <td></td> <td></td> <td>D DF L LF LR RF RR</td> <td><input type="checkbox"/></td> <td><input type="checkbox"/></td> </tr> <tr> <td></td> <td></td> <td></td> <td>D DF L LF LR RF RR</td> <td><input type="checkbox"/></td> <td><input type="checkbox"/></td> </tr> <tr> <td></td> <td></td> <td></td> <td>D DF L LF LR RF RR</td> <td><input type="checkbox"/></td> <td><input type="checkbox"/></td> </tr> </tbody> </table>	ID#	Color	Type	Placement (Circle One)	Applied	Present				D DF L LF LR RF RR	<input type="checkbox"/>	<input type="checkbox"/>				D DF L LF LR RF RR	<input type="checkbox"/>	<input type="checkbox"/>				D DF L LF LR RF RR	<input type="checkbox"/>	<input type="checkbox"/>	WHOLE CARCASS DISPOSAL (Check one or more) <input checked="" type="checkbox"/> 1. Left at Site <input type="checkbox"/> 4. Rendered <input type="checkbox"/> 7. Unknown <input type="checkbox"/> 2. Buried <input type="checkbox"/> 5. Sunk <input type="checkbox"/> 3. Towed <input type="checkbox"/> 6. Frozen for Later Examination
ID#	Color	Type	Placement (Circle One)	Applied	Present																				
			D DF L LF LR RF RR	<input type="checkbox"/>	<input type="checkbox"/>																				
			D DF L LF LR RF RR	<input type="checkbox"/>	<input type="checkbox"/>																				
			D DF L LF LR RF RR	<input type="checkbox"/>	<input type="checkbox"/>																				

SPECIMEN DISPOSITION (Check one or more)
 1. Scientific Collection
 2. Educational Collection
 3. Other: _____

Comments: Removed head/fetus*
gave to NMFS

NECROPSIED YES NO Date: _____
 NECROPSIED BY: _____

6/23/03

CHG 10
10/7/76

RECEIVED BY
10-10-76 10:00

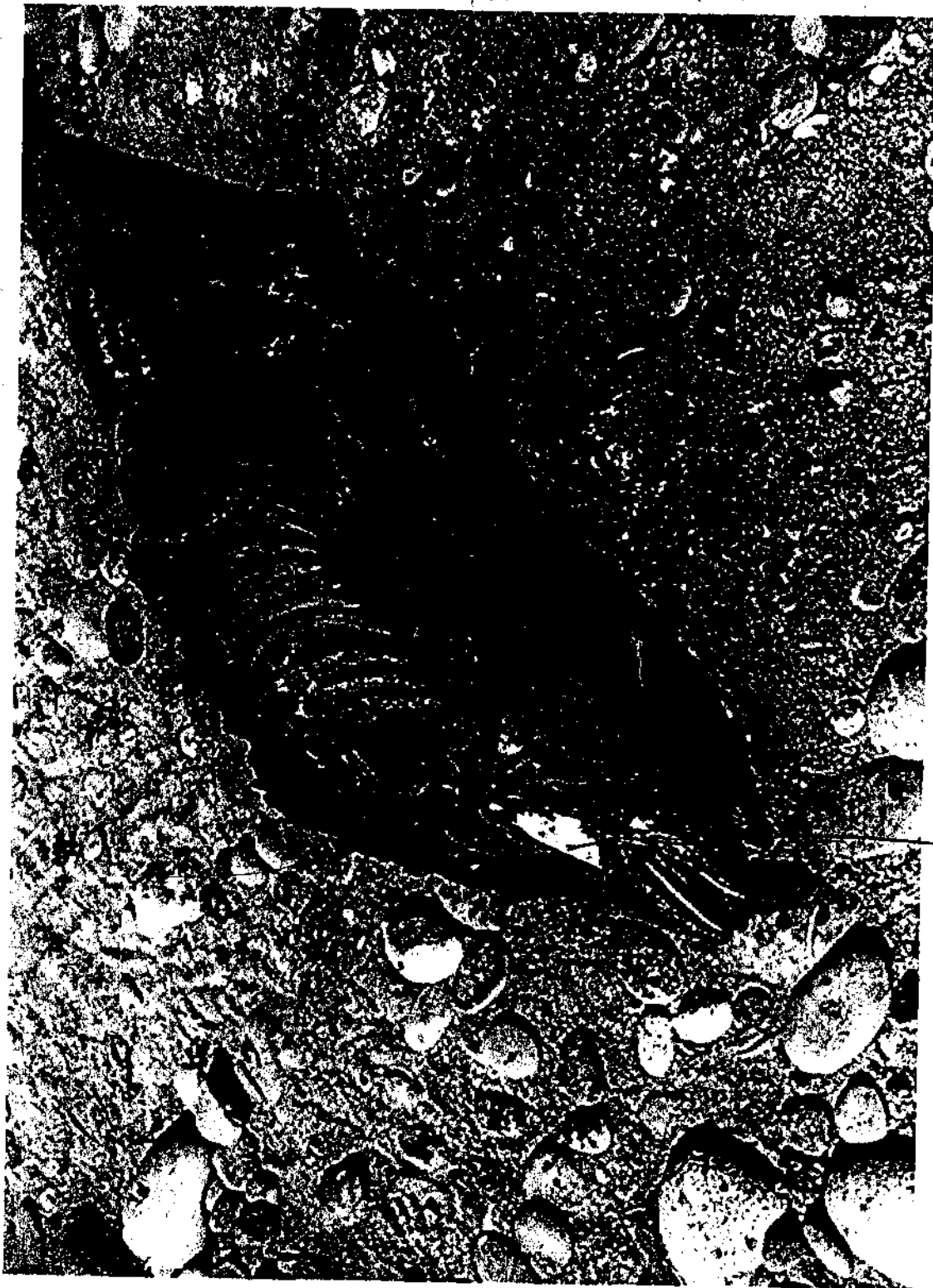PLEASE USE BACK SIDE FOR THIS DOCUMENT

RECEIVED BY

RECEIVED BY

DATE

TIME



Bone

MARINE MAMMAL STRANDING REPORT - LEVEL A DATA

FIELD #: DN6 03 003 NMFS REGIONAL: 03ND R05094 NATIONAL DATABASE # 116-2003-1000

COMMON NAME: harbor porpoise GENUS: Phocoena SPECIES: phocoena

EXAMINER: _____ Letterholder: _____

Name: _____ Affiliation: U.S. Fish & Wildlife Service

Address: Port Angeles, CA Phone: _____

LOCATION State: <u>WA</u> County: <u>Clallam</u> City: <u>Sequim</u> Locality Details: <u>2 miles south of Wangness Spit</u> Latitude: _____ N Longitude: _____ W	OCCURRENCE DETAILS Mass Stranding: <input type="checkbox"/> YES <input checked="" type="checkbox"/> NO Signs of Human Interaction: <input type="checkbox"/> YES <input type="checkbox"/> NO (Check one or more) <input type="checkbox"/> 1. Boat Collision <input type="checkbox"/> 3. Fishery Interaction <input type="checkbox"/> 2. Shot <input type="checkbox"/> 4. Other Human Interaction: _____ How determined: <input type="checkbox"/> External Exam <input type="checkbox"/> Internal Exam <input type="checkbox"/> Not Examined Other Causes: <input type="checkbox"/> YES <input type="checkbox"/> NO <input type="checkbox"/> GBD Describe: _____
---	---

DATE OF INITIAL OBSERVATION Year: <u>2003</u> Month: <u>5</u> Day: <u>4</u> <u>By Refuge visitors</u> STATUS (Check ONE) <input type="checkbox"/> 1. Alive <input checked="" type="checkbox"/> 4. Advanced Decomposition <u>Described as Scavenged</u> <input type="checkbox"/> 2. Fresh Dead <input type="checkbox"/> 5. Mummified/Skeletal <input type="checkbox"/> 3. Moderate Decomposition <input type="checkbox"/> 6. Dead - Condition Unknown	DATE OF EXAMINATION (LEVEL A) <input checked="" type="checkbox"/> Not Able to Examine Year: _____ Month: _____ Day: _____ <u>could not locate</u> CONDITION (Check ONE) <input type="checkbox"/> 1. Alive <input type="checkbox"/> 4. Advanced Decomposition <input type="checkbox"/> 2. Fresh Dead <input type="checkbox"/> 5. Mummified/Skeletal <input type="checkbox"/> 3. Moderate Decomposition <input type="checkbox"/> 6. Dead - Condition Unknown
---	---

INITIAL LIVE ANIMAL DISPOSITION (Check one or more) <input type="checkbox"/> 1. Left at Site <input type="checkbox"/> 5. Euthanized at Site <input type="checkbox"/> 2. Immediate Release at Site <input type="checkbox"/> 6. Died at Site <input type="checkbox"/> 3. Relocated <input type="checkbox"/> 7. Transferred to Rehabilitation <input type="checkbox"/> 4. Disentangled <input type="checkbox"/> 8. Died During Transport <input type="checkbox"/> 9. Other _____ CONDITION (Check ONE) <input type="checkbox"/> 1. Sick <input type="checkbox"/> 3. Apparently Healthy <input type="checkbox"/> 5. Other _____ <input type="checkbox"/> 2. Injured <input type="checkbox"/> 4. Out of Habitat Date: _____ Rehabilitation Facility: _____ Comments: _____	MORPHOLOGICAL DATA SEX (Check ONE) AGE CLASS (Check ONE) <input type="checkbox"/> 1. Male <input type="checkbox"/> 1. Adult <input type="checkbox"/> 4. Pup/Calf <input type="checkbox"/> 2. Female <input type="checkbox"/> 2. Subadult <input type="checkbox"/> 5. Unknown <input type="checkbox"/> 3. Unknown <input type="checkbox"/> 3. Yearling Straight Length: _____ <input type="checkbox"/> cm <input type="checkbox"/> in <input type="checkbox"/> actual <input type="checkbox"/> estimate Weight: _____ <input type="checkbox"/> kg <input type="checkbox"/> lb <input type="checkbox"/> actual <input type="checkbox"/> estimate PHOTOS/VIDEOS TAKEN: <input type="checkbox"/> YES <input type="checkbox"/> NO Disposition: <u>described as smaller than 2nd animal - ? - 84cm</u>
---	--

TAG DATA <table border="1" style="width: 100%; border-collapse: collapse;"> <thead> <tr> <th>ID#</th> <th>Color</th> <th>Type</th> <th>*Placement (Circle One)</th> <th>Applied</th> <th>Present</th> </tr> </thead> <tbody> <tr> <td> </td> <td> </td> <td> </td> <td>D DF L LF LR RF RR</td> <td style="text-align: center;"><input type="checkbox"/></td> <td style="text-align: center;"><input type="checkbox"/></td> </tr> <tr> <td> </td> <td> </td> <td> </td> <td>D DF L LF LR RF RR</td> <td style="text-align: center;"><input type="checkbox"/></td> <td style="text-align: center;"><input type="checkbox"/></td> </tr> <tr> <td> </td> <td> </td> <td> </td> <td>D DF L LF LR RF RR</td> <td style="text-align: center;"><input type="checkbox"/></td> <td style="text-align: center;"><input type="checkbox"/></td> </tr> </tbody> </table>	ID#	Color	Type	*Placement (Circle One)	Applied	Present				D DF L LF LR RF RR	<input type="checkbox"/>	<input type="checkbox"/>				D DF L LF LR RF RR	<input type="checkbox"/>	<input type="checkbox"/>				D DF L LF LR RF RR	<input type="checkbox"/>	<input type="checkbox"/>	WHOLE CARCASS DISPOSAL (Check one or more) <input type="checkbox"/> 1. Left at Site <input type="checkbox"/> 4. Rendered <input type="checkbox"/> 7. Unknown <input type="checkbox"/> 2. Buried <input type="checkbox"/> 5. Sunk <input type="checkbox"/> 3. Towed <input type="checkbox"/> 6. Frozen for Later Examination SPECIMEN DISPOSITION (Check one or more) <input type="checkbox"/> 1. Scientific Collection <input type="checkbox"/> 2. Educational Collection <input type="checkbox"/> 3. Other: _____ Comments: _____
ID#	Color	Type	*Placement (Circle One)	Applied	Present																				
			D DF L LF LR RF RR	<input type="checkbox"/>	<input type="checkbox"/>																				
			D DF L LF LR RF RR	<input type="checkbox"/>	<input type="checkbox"/>																				
			D DF L LF LR RF RR	<input type="checkbox"/>	<input type="checkbox"/>																				

ADDITIONAL COMMENTS: _____

NECROPSIED: YES NO Date: _____

NECROPSIED BY: _____

6/23/03

MARINE MAMMAL STRANDING REPORT

NOA 2002-105-718

SID# _____ (NMFS USE)

FIELD NO.: 2003-SJ007 NMFS REGISTRATION NO.: 03MUK0005

COMMON NAME: Harbor Porpoise GENUS: Phocoena SPECIES: phocoena

EXAMINER Name: _____ Agency: The Whale Museum Phone: _____

Address: _____ Friday Harbor WA

LOCATION State: <u>WA</u> County: <u>San Juan</u> City: _____ Locality Details: _____ <u>Jackson Beach</u> <u>San Juan Island</u> *Latitude: _____ N *Longitude: _____ W	TYPE OF OCCURRENCE Mass Stranding: <input type="checkbox"/> Yes <input checked="" type="checkbox"/> No # Animals <u>1</u> Human Interaction: <input checked="" type="checkbox"/> Yes <input type="checkbox"/> No <input checked="" type="checkbox"/> ? Check one: <input type="checkbox"/> 1. Boat Collision <input type="checkbox"/> 2. Shot <input checked="" type="checkbox"/> 3. Fishery Interaction <input type="checkbox"/> 4. Other _____ How determined: <u>Tangled in Fishing Net</u> Other Causes (if known): _____
--	--

DATE OF INITIAL OBSERVATION:
 Yr. 2003 Mo. 5 Day 4

CONDITION: Check one: 1. Alive
 2. Fresh dead
 3. Moderate decomp.
 4. Advanced decomp.
 5. Mummified
 6. Unknown

DATE OF EXAMINATION:
 Yr. 2003 Mo. 5 Day 5

CONDITION: Check one: 1. Alive
 2. Fresh dead
 3. Moderate decomp.
 4. Advanced decomp.
 5. Mummified
 6. Unknown

LIVE ANIMAL — Condition and Disposition:
 Check one or more: 1. Released at site
 2. Sick
 3. Injured
 4. Died
 5. Euthanized
 6. Rehabilitated and released
 7. Unknown

Transported to: _____
 Died Released Date: _____

TAGS APPLIED?: Yes No
TAGS PRESENT?: Yes No

	Dorsal	Left	Right
Tag No.(s):	_____	_____	_____
Color(s):	_____	_____	_____
Type:	_____	_____	_____
Placement		Front/Rear	Front/Rear

CARCASS — Disposition:
 Check one: 1. Left at site
 2. Buried
 3. Towed
 4. Sci. collection: (see below)
 5. Edu. collection: (see below)
 6. Other _____
 7. Unknown

NECROPSIED? Yes No 7/24/03

MORPHOLOGICAL DATA:
 Sex — Check one: 1. Male
 2. Female
 3. Unknown

Straight Length: 126 cm in est
 *Weight _____ kg lb est

PHOTOS TAKEN? Yes No

REMARKS: Collected for Necropsy. Stored in FHL freezer.

DISPOSITION OF TISSUE/SKELETAL MATERIAL: _____

6/23/03

MARINE MAMMAL STRANDING REPORT

NW-2005-100-779
SID# _____ (NMFS USE)
TO SCW 7/12/03

FIELD NO.: 2003-5J008 NMFS REGISTRATION NO.: 03NWR05006

COMMON NAME: Harbor porpoise GENUS: Phocoena SPECIES: phocoena

EXAMINER Name: Whale Museum Agency: _____ Phone: _____

Address: _____

LOCATION State: <u>WA</u> County: <u>San Juan</u> City: _____ Locality Details: _____ <u>South Beach,</u> <u>San Juan Island</u> *Latitude: _____ N *Longitude: _____ W	TYPE OF OCCURRENCE Mass Stranding: <input type="checkbox"/> Yes <input checked="" type="checkbox"/> No # Animals <u>1</u> Human Interaction: <input type="checkbox"/> Yes <input type="checkbox"/> No <input checked="" type="checkbox"/> ? Check one: <input type="checkbox"/> 1. Boat Collision <input type="checkbox"/> 2. Shot <input type="checkbox"/> 3. Fishery Interaction <input type="checkbox"/> 4. Other _____ How determined: _____ Other Causes (if known): _____
---	--

DATE OF INITIAL OBSERVATION: Yr. <u>2003</u> Mo. <u>5</u> Day <u>5</u> CONDITION: Check one: <input type="checkbox"/> 1. Alive <input type="checkbox"/> 2. Fresh dead <input checked="" type="checkbox"/> 3. Moderate decomp. <input type="checkbox"/> 4. Advanced decomp. <input type="checkbox"/> 5. Mummified <input type="checkbox"/> 7. Unknown	DATE OF EXAMINATION: Yr. <u>2003</u> Mo. <u>5</u> Day <u>5</u> CONDITION: Check one: <input type="checkbox"/> 1. Alive <input type="checkbox"/> 2. Fresh dead <input checked="" type="checkbox"/> 3. Moderate decomp. <input type="checkbox"/> 4. Advanced decomp. <input type="checkbox"/> 5. Mummified <input type="checkbox"/> 7. Unknown
--	--

LIVE ANIMAL — Condition and Disposition: Check one or more: <input type="checkbox"/> 1. Released at site <input type="checkbox"/> 2. Sick <input type="checkbox"/> 3. Injured <input type="checkbox"/> 4. Died <input type="checkbox"/> 5. Euthanized <input type="checkbox"/> 6. Rehabilitated and released <input type="checkbox"/> 7. Unknown Transported to: _____ <input type="checkbox"/> Died <input type="checkbox"/> Released Date: _____	TAGS APPLIED?: <input type="checkbox"/> Yes <input checked="" type="checkbox"/> No TAGS PRESENT?: <input type="checkbox"/> Yes <input checked="" type="checkbox"/> No <table border="0"><tr><td></td><td>Dorsal</td><td>Left</td><td>Right</td></tr><tr><td>Tag No.(s):</td><td>_____</td><td>_____</td><td>_____</td></tr><tr><td>Color(s):</td><td>_____</td><td>_____</td><td>_____</td></tr><tr><td>Type:</td><td>_____</td><td>_____</td><td>_____</td></tr><tr><td>Placement</td><td></td><td>Front/Rear</td><td>Front/Rear</td></tr></table>		Dorsal	Left	Right	Tag No.(s):	_____	_____	_____	Color(s):	_____	_____	_____	Type:	_____	_____	_____	Placement		Front/Rear	Front/Rear
	Dorsal	Left	Right																		
Tag No.(s):	_____	_____	_____																		
Color(s):	_____	_____	_____																		
Type:	_____	_____	_____																		
Placement		Front/Rear	Front/Rear																		

CARCASS — Disposition: Check one: <input type="checkbox"/> 1. Left at site <input type="checkbox"/> 2. Buried <input type="checkbox"/> 3. Towed <input checked="" type="checkbox"/> 4. Sci. collection: (see below) <input type="checkbox"/> 5. Edu. collection: (see below) <input type="checkbox"/> 6. Other _____ <input type="checkbox"/> 7. Unknown NECROPSIED? <input checked="" type="checkbox"/> Yes <input type="checkbox"/> No <u>7/23/03</u>	MORPHOLOGICAL DATA: Sex — Check one: <input type="checkbox"/> 1. Male <input checked="" type="checkbox"/> 2. Female <input type="checkbox"/> 7. Unknown Straight Length: <u>152 cm</u> <input type="checkbox"/> cm <input type="checkbox"/> in <input type="checkbox"/> est *Weight _____ <input type="checkbox"/> kg <input type="checkbox"/> lb <input type="checkbox"/> est PHOTOS TAKEN? <input checked="" type="checkbox"/> Yes* <input type="checkbox"/> No <i>*during necropsy</i>
--	---

REMARKS: collected for necropsy. Stored in FHL freezer.

DISPOSITION OF TISSUE/SKELETAL MATERIAL: _____

6/23/03

MARINE MAMMAL STRANDING REPORT - LEVEL A DATA

TO Scan 7/7
yes

NW-2003-700781

FIELD #: DCNM503 Pp 01 NMFS REGIONAL #: 03NWR05008 NATIONAL DATABASE #: _____
 COMMON NAME: Harbor Porpoise GENUS: Phocoena SPECIES: phocoena
 EXAMINER: _____ Letterholder: _____
 Name: _____ Affiliation: Olympic Coast National Marine Sanctuary
 Address: _____, Port Angeles WA Phone: _____

LOCATION State: <u>WA</u> County: <u>Clallam</u> City: <u>Port Angeles</u> Locality Details: <u>On Discovery trail east of mp 2 at river delta/bridge.</u> Latitude: _____ N Longitude: _____ W	OCCURRENCE DETAILS Mass Stranding: <input type="checkbox"/> YES <input checked="" type="checkbox"/> NO # Animals: _____ MS#: _____ (NMFS USE) Signs of Human Interaction: <input type="checkbox"/> YES <input checked="" type="checkbox"/> NO <input type="checkbox"/> Could Not be Determined (CBD) (Check one or more) <input type="checkbox"/> 1. Boat Collision <input type="checkbox"/> 3. Fishery Interaction <input type="checkbox"/> 2. Shot <input type="checkbox"/> 4. Other Human Interaction: _____ How determined: <input checked="" type="checkbox"/> External Exam <input type="checkbox"/> Internal Exam <input type="checkbox"/> Not Examined Other Causes: <input type="checkbox"/> YES <input type="checkbox"/> NO <input type="checkbox"/> CBD Describe: _____
---	---

DATE OF INITIAL OBSERVATION Year: <u>2003</u> Month: <u>5</u> Day: <u>96</u> STATUS (Check ONE) <input type="checkbox"/> 1. Alive <input type="checkbox"/> 4. Advanced Decomposition <input type="checkbox"/> 2. Fresh Dead <input type="checkbox"/> 5. Mummified/Skeletal <input checked="" type="checkbox"/> 3. Moderate Decomposition <input type="checkbox"/> 6. Dead - Condition Unknown	DATE OF EXAMINATION (LEVEL A) <input type="checkbox"/> Not Able to Examine Year: _____ Month: _____ Day: _____ CONDITION (Check ONE) <input type="checkbox"/> 1. Alive <input type="checkbox"/> 4. Advanced Decomposition <input type="checkbox"/> 2. Fresh Dead <input type="checkbox"/> 5. Mummified/Skeletal <input type="checkbox"/> 3. Moderate Decomposition <input type="checkbox"/> 6. Dead - Condition Unknown
--	--

INITIAL LIVE ANIMAL DISPOSITION (Check one or more) <input type="checkbox"/> 1. Left at Site <input type="checkbox"/> 5. Euthanized at Site <input type="checkbox"/> 2. Immediate Release at Site <input type="checkbox"/> 6. Died at Site <input type="checkbox"/> 3. Relocated <input type="checkbox"/> 7. Transferred to Rehabilitation <input type="checkbox"/> 4. Disentangled <input type="checkbox"/> 8. Died During Transport <input type="checkbox"/> 9. Other CONDITION (Check ONE) <input type="checkbox"/> 1. Sick <input type="checkbox"/> 3. Apparently Healthy <input type="checkbox"/> 5. Other <input type="checkbox"/> 2. Injured <input type="checkbox"/> 4. Out of Habitat Date: _____ Rehabilitation Facility: _____ Comments: _____	MORPHOLOGICAL DATA SEX (Check ONE) <input checked="" type="checkbox"/> 1. Male <input type="checkbox"/> 2. Female <input type="checkbox"/> 3. Unknown AGE CLASS (Check ONE) <input checked="" type="checkbox"/> 1. Adult <input type="checkbox"/> 2. Subadult <input type="checkbox"/> 3. Yearling <input type="checkbox"/> 4. Pup/Calf <input type="checkbox"/> 5. Unknown Straight Length: <u>146</u> <input checked="" type="checkbox"/> cm <input type="checkbox"/> in <input checked="" type="checkbox"/> actual <input type="checkbox"/> estimate Weight: _____ <input type="checkbox"/> kg <input type="checkbox"/> lb <input type="checkbox"/> actual <input type="checkbox"/> estimate PHOTOS/VIDEOS TAKEN: <input checked="" type="checkbox"/> YES <input type="checkbox"/> NO Disposition: <u>cut off head & froze for scanning. delivered by _____ to NMFS -</u>
---	---

TAG DATA <table border="1" style="width: 100%; border-collapse: collapse;"> <thead> <tr> <th>ID#</th> <th>Color</th> <th>Type</th> <th>*Placement (Circle One)</th> <th>Applied</th> <th>Present</th> </tr> </thead> <tbody> <tr> <td>_____</td> <td>_____</td> <td>_____</td> <td>D DF L LF LR RF RR</td> <td><input type="checkbox"/></td> <td><input type="checkbox"/></td> </tr> <tr> <td>_____</td> <td>_____</td> <td>_____</td> <td>D DF L LF LR RF RR</td> <td><input type="checkbox"/></td> <td><input type="checkbox"/></td> </tr> <tr> <td>_____</td> <td>_____</td> <td>_____</td> <td>D DF L LF LR RF RR</td> <td><input type="checkbox"/></td> <td><input type="checkbox"/></td> </tr> </tbody> </table> <p>*D=Dorsal; DF=Dorsal Fin; L=Lateral Body LF=Left Front; LR=Left Rear; RF=Right Front; RR=Right Rear</p>	ID#	Color	Type	*Placement (Circle One)	Applied	Present	_____	_____	_____	D DF L LF LR RF RR	<input type="checkbox"/>	<input type="checkbox"/>	_____	_____	_____	D DF L LF LR RF RR	<input type="checkbox"/>	<input type="checkbox"/>	_____	_____	_____	D DF L LF LR RF RR	<input type="checkbox"/>	<input type="checkbox"/>	WHOLE CARCASS DISPOSAL (Check one or more) <input checked="" type="checkbox"/> 1. Left at Site <u>except head</u> <input type="checkbox"/> 4. Rendered <input type="checkbox"/> 7. Unknown <input type="checkbox"/> 2. Buried <input type="checkbox"/> 5. Sunk <input type="checkbox"/> 3. Towed <input type="checkbox"/> 6. Frozen for Later Examination SPECIMEN DISPOSITION (Check one or more) <input checked="" type="checkbox"/> 1. Scientific Collection <input type="checkbox"/> 2. Educational Collection <input type="checkbox"/> 3. Other: _____ Comments: <u>Timing near Canadian Navy Test Puns collected for scanning.</u> NECROPSIED <input checked="" type="checkbox"/> YES <input type="checkbox"/> NO Date: <u>head 7/22/03 body 7/23/03</u> NECROPSIED BY: _____
ID#	Color	Type	*Placement (Circle One)	Applied	Present																				
_____	_____	_____	D DF L LF LR RF RR	<input type="checkbox"/>	<input type="checkbox"/>																				
_____	_____	_____	D DF L LF LR RF RR	<input type="checkbox"/>	<input type="checkbox"/>																				
_____	_____	_____	D DF L LF LR RF RR	<input type="checkbox"/>	<input type="checkbox"/>																				

6/23/03

OVER →

ADDITIONAL REMARKS

ADDITIONAL IDENTIFIER:

First called in by woman (- AA Acupuncture center) when she saw it on Tuesday 5/6 - took her awhile to find right contact. She contacted the Sanctuary on 5/9/03.

DISCLAIMER

These data should not be used out of context or without verification. This should be strictly enforced when reporting signs of human interaction data.

DATA ACCESS FOR LEVEL A DATA

Upon written request, certain fields of the Level A Data Sheet will be released to the requestor provided that the requestor credit the stranding network and the National Marine Fisheries Service. The National Marine Fisheries Service will notify the contributing stranding network members that these data have been requested and the intent of use. All other data will be released to the requestor provided that the requestor obtain permission from the contributing stranding network and the National Marine Fisheries Service.

PAPERWORK REDUCTION ACT INFORMATION

Public reporting burden for the collection of information is estimated to average 20 minutes per response, including the time for reviewing instructions, searching existing data sources, gathering and maintaining the data needed, and completing and reviewing the collection of information. Send comments regarding this burden estimate or any other aspect of the collection of information, including suggestions for reducing the burden to: Chief, Marine Mammal Conservation Division, Office of Protected Resources, NOAA Fisheries, 1315 East-West Highway, Silver Spring, Maryland 20910. Notwithstanding any other provision of the law, no person is required to respond to, nor shall any person be subjected to a penalty for failure to comply with, a collection of information subject to the requirements of the Paperwork Reduction Act, unless the collection of information displays a currently valid Office of Management and Budget (OMB) Control Number.



MARINE MAMMAL STRANDING REPORT - LEVEL A DATA

FIELD #: 03-IS-160 NMFS REGIONAL #: 03NWR05033 NATIONAL DATABASE #: _____
(NMFS USE) (NMFS USE)

COMMON NAME: Harbor Porpoise GENUS: Phocoena SPECIES: phocoena

EXAMINER: _____ Letterholder: _____

Name: W & J Beach Watchers Affiliation: _____

Address: _____ Phone: _____

LOCATION State: <u>VA</u> County: <u>Island</u> City: _____ Locality Details: <u>West Beach</u> <u>Whidbey Isl.</u> Latitude: _____ N Longitude: _____ W	OCCURRENCE DETAILS Mass Stranding: <input type="checkbox"/> YES <input checked="" type="checkbox"/> NO # Animals: <u>1</u> MS#: _____ <small>(NMFS USE)</small> Signs of Human Interaction: <input type="checkbox"/> YES <input type="checkbox"/> NO <input checked="" type="checkbox"/> Could Not be Determined (CBD) (Check one or more) <input type="checkbox"/> 1. Boat Collision <input type="checkbox"/> 3. Fishery Interaction <input type="checkbox"/> 2. Shot <input type="checkbox"/> 4. Other Human Interaction: _____ How determined: <input type="checkbox"/> External Exam <input type="checkbox"/> Internal Exam <input checked="" type="checkbox"/> Not Examined Other Causes: <input type="checkbox"/> YES <input type="checkbox"/> NO <input checked="" type="checkbox"/> CBD Describe: _____
---	---

DATE OF INITIAL OBSERVATION Year: <u>03</u> Month: <u>05</u> Day: <u>12</u> STATUS (Check ONE) <input type="checkbox"/> 1. Alive <input type="checkbox"/> 4. Advanced Decomposition <input type="checkbox"/> 2. Fresh Dead <input type="checkbox"/> 5. Mummified/Skeletal <input type="checkbox"/> 3. Moderate Decomposition <input checked="" type="checkbox"/> 6. Dead - Condition Unknown	DATE OF EXAMINATION (LEVEL A) <input checked="" type="checkbox"/> Not Able to Examine Year: _____ Month: _____ Day: _____ CONDITION (Check ONE) <input type="checkbox"/> 1. Alive <input type="checkbox"/> 4. Advanced Decomposition <input type="checkbox"/> 2. Fresh Dead <input type="checkbox"/> 5. Mummified/Skeletal <input type="checkbox"/> 3. Moderate Decomposition <input type="checkbox"/> 6. Dead - Condition Unknown
---	---

INITIAL LIVE ANIMAL DISPOSITION (Check one or more) <input type="checkbox"/> 1. Left at Site <input type="checkbox"/> 5. Euthanized at Site <input type="checkbox"/> 2. Immediate Release at Site <input type="checkbox"/> 6. Died at Site <input type="checkbox"/> 3. Relocated <input type="checkbox"/> 7. Transferred to Rehabilitation <input type="checkbox"/> 4. Disentangled <input type="checkbox"/> 8. Died During Transport <input type="checkbox"/> 9. Other CONDITION (Check ONE) <input type="checkbox"/> 1. Sick <input type="checkbox"/> 3. Apparently Healthy <input type="checkbox"/> 5. Other <input type="checkbox"/> 2. Injured <input type="checkbox"/> 4. Out of Habitat Date: _____ Rehabilitation Facility: _____ Comments: _____	MORPHOLOGICAL DATA SEX (Check ONE) AGE CLASS (Check ONE) <input type="checkbox"/> 1. Male <input type="checkbox"/> 1. Adult <input type="checkbox"/> 4. Pup/Calf <input type="checkbox"/> 2. Female <input type="checkbox"/> 2. Subadult <input checked="" type="checkbox"/> 5. Unknown <input checked="" type="checkbox"/> 3. Unknown <input type="checkbox"/> 3. Yearling Straight Length: _____ <input type="checkbox"/> cm <input type="checkbox"/> in <input type="checkbox"/> actual <input type="checkbox"/> estimate Weight: _____ <input type="checkbox"/> kg <input type="checkbox"/> lb <input type="checkbox"/> actual <input type="checkbox"/> estimate PHOTOS/VIDEOS TAKEN: <input type="checkbox"/> YES <input checked="" type="checkbox"/> NO Disposition: _____
---	--

TAG DATA <table style="width: 100%; border-collapse: collapse;"> <thead> <tr> <th style="text-align: left;">ID#</th> <th style="text-align: left;">Color</th> <th style="text-align: left;">Type</th> <th style="text-align: left;">*Placement (Circle One)</th> <th style="text-align: center;">Applied</th> <th style="text-align: center;">Present</th> </tr> </thead> <tbody> <tr> <td>_____</td> <td>_____</td> <td>_____</td> <td>D DF L LF LR RF RR</td> <td style="text-align: center;"><input type="checkbox"/></td> <td style="text-align: center;"><input type="checkbox"/></td> </tr> <tr> <td>_____</td> <td>_____</td> <td>_____</td> <td>D DF L LF LR RF RR</td> <td style="text-align: center;"><input type="checkbox"/></td> <td style="text-align: center;"><input type="checkbox"/></td> </tr> <tr> <td>_____</td> <td>_____</td> <td>_____</td> <td>D DF L LF LR RF RR</td> <td style="text-align: center;"><input type="checkbox"/></td> <td style="text-align: center;"><input type="checkbox"/></td> </tr> </tbody> </table> <p><small>*D=Dorsal; DF=Dorsal Fin; L=Lateral Body LF=Left Front; LR=Left Rear; RF=Right Front; RR=Right Rear</small></p>	ID#	Color	Type	*Placement (Circle One)	Applied	Present	_____	_____	_____	D DF L LF LR RF RR	<input type="checkbox"/>	<input type="checkbox"/>	_____	_____	_____	D DF L LF LR RF RR	<input type="checkbox"/>	<input type="checkbox"/>	_____	_____	_____	D DF L LF LR RF RR	<input type="checkbox"/>	<input type="checkbox"/>	WHOLE CARCASS DISPOSAL (Check one or more) <input checked="" type="checkbox"/> 1. Left at Site <input type="checkbox"/> 4. Rendered <input checked="" type="checkbox"/> 7. Unknown <input type="checkbox"/> 2. Buried <input type="checkbox"/> 5. Sunk <input type="checkbox"/> 3. Towed <input type="checkbox"/> 6. Frozen for Later Examination SPECIMEN DISPOSITION (Check one or more) <input type="checkbox"/> 1. Scientific Collection <input type="checkbox"/> 2. Educational Collection <input type="checkbox"/> 3. Other: _____ Comments: <u>not collected</u> NECROPSIED <input type="checkbox"/> YES <input checked="" type="checkbox"/> NO Date: _____ NECROPSIED BY: _____
ID#	Color	Type	*Placement (Circle One)	Applied	Present																				
_____	_____	_____	D DF L LF LR RF RR	<input type="checkbox"/>	<input type="checkbox"/>																				
_____	_____	_____	D DF L LF LR RF RR	<input type="checkbox"/>	<input type="checkbox"/>																				
_____	_____	_____	D DF L LF LR RF RR	<input type="checkbox"/>	<input type="checkbox"/>																				

MARINE MAMMAL STRANDING REPORT - LEVEL A DATA

FIELD #: 03 - GH - 159 NMFS REGIONAL #: 03NWR05034 NATIONAL DATABASE #: _____
(NMFS USE) (NMFS USE)

COMMON NAME: Harbor Porpoise GENUS: Phocoena SPECIES: phocoena

EXAMINER Name: Cascadia Research Letterholder: _____
 Affiliation: _____

Address: _____ Phone: _____

LOCATION State: <u>WA</u> County: <u>Grays Harbor</u> City: <u>Ocean City</u> Locality Details: _____ _____ Latitude: _____ N Longitude: _____ W	OCCURRENCE DETAILS Mass Stranding: <input type="checkbox"/> YES <input checked="" type="checkbox"/> NO # Animals: <u>1</u> MS#: _____ <small>(NMFS USE)</small> Signs of Human Interaction: <input type="checkbox"/> YES <input type="checkbox"/> NO <input checked="" type="checkbox"/> Could Not be Determined (CBD) (Check one or more) <input type="checkbox"/> 1. Boat Collision <input type="checkbox"/> 3. Fishery Interaction <input type="checkbox"/> 2. Shot <input type="checkbox"/> 4. Other Human Interaction: _____ How determined: <input type="checkbox"/> External Exam <input type="checkbox"/> Internal Exam <input checked="" type="checkbox"/> Not Examined Other Causes: <input type="checkbox"/> YES <input type="checkbox"/> NO <input checked="" type="checkbox"/> CBD Describe: _____
---	---

DATE OF INITIAL OBSERVATION Year: <u>03</u> Month: <u>05</u> Day: <u>12</u> STATUS (Check ONE) <input type="checkbox"/> 1. Alive <input type="checkbox"/> 4. Advanced Decomposition <input type="checkbox"/> 2. Fresh Dead <input type="checkbox"/> 5. Mummified/Skeletal <input checked="" type="checkbox"/> 3. Moderate Decomposition <input type="checkbox"/> 6. Dead - Condition Unknown	DATE OF EXAMINATION (LEVEL A) <input checked="" type="checkbox"/> Not Able to Examine Year: _____ Month: _____ Day: _____ CONDITION (Check ONE) <input type="checkbox"/> 1. Alive <input type="checkbox"/> 4. Advanced Decomposition <input type="checkbox"/> 2. Fresh Dead <input type="checkbox"/> 5. Mummified/Skeletal <input type="checkbox"/> 3. Moderate Decomposition <input type="checkbox"/> 6. Dead - Condition Unknown
---	---

INITIAL LIVE ANIMAL DISPOSITION (Check one or more) <input type="checkbox"/> 1. Left at Site <input type="checkbox"/> 5. Euthanized at Site <input type="checkbox"/> 2. Immediate Release at Site <input type="checkbox"/> 6. Died at Site <input type="checkbox"/> 3. Relocated <input type="checkbox"/> 7. Transferred to Rehabilitation <input type="checkbox"/> 4. Disentangled <input type="checkbox"/> 8. Died During Transport <input type="checkbox"/> 9. Other CONDITION (Check ONE) <input type="checkbox"/> 1. Sick <input type="checkbox"/> 3. Apparently Healthy <input type="checkbox"/> 5. Other <input type="checkbox"/> 2. Injured <input type="checkbox"/> 4. Out of Habitat Date: _____ Rehabilitation Facility: _____ Comments: _____	MORPHOLOGICAL DATA SEX (Check ONE) AGE CLASS (Check ONE) <input type="checkbox"/> 1. Male <input type="checkbox"/> 1. Adult <input type="checkbox"/> 4. Pup/Calf <input type="checkbox"/> 2. Female <input type="checkbox"/> 2. Subadult <input checked="" type="checkbox"/> 5. Unknown <input checked="" type="checkbox"/> 3. Unknown <input type="checkbox"/> 3. Yearling Straight Length: _____ <input type="checkbox"/> cm <input type="checkbox"/> in <input type="checkbox"/> actual <input type="checkbox"/> estimate Weight: _____ <input type="checkbox"/> kg <input type="checkbox"/> lb <input type="checkbox"/> actual <input type="checkbox"/> estimate PHOTOS/VIDEOS TAKEN: <input type="checkbox"/> YES <input checked="" type="checkbox"/> NO Disposition: _____
---	---

TAG DATA <table style="width: 100%; border-collapse: collapse;"> <thead> <tr> <th>ID#</th> <th>Color</th> <th>Type</th> <th>*Placement (Circle One)</th> <th>Applied</th> <th>Present</th> </tr> </thead> <tbody> <tr> <td>_____</td> <td>_____</td> <td>_____</td> <td>D DF L LF LR RF RR</td> <td style="text-align: center;"><input type="checkbox"/></td> <td style="text-align: center;"><input type="checkbox"/></td> </tr> <tr> <td>_____</td> <td>_____</td> <td>_____</td> <td>D DF L LF LR RF RR</td> <td style="text-align: center;"><input type="checkbox"/></td> <td style="text-align: center;"><input type="checkbox"/></td> </tr> <tr> <td>_____</td> <td>_____</td> <td>_____</td> <td>D DF L LF LR RF RR</td> <td style="text-align: center;"><input type="checkbox"/></td> <td style="text-align: center;"><input type="checkbox"/></td> </tr> </tbody> </table> <p><small>*D=Dorsal; DF=Dorsal Fin; L=Lateral Body LF=Left Front; LR=Left Rear; RF=Right Front; RR=Right Rear</small></p>	ID#	Color	Type	*Placement (Circle One)	Applied	Present	_____	_____	_____	D DF L LF LR RF RR	<input type="checkbox"/>	<input type="checkbox"/>	_____	_____	_____	D DF L LF LR RF RR	<input type="checkbox"/>	<input type="checkbox"/>	_____	_____	_____	D DF L LF LR RF RR	<input type="checkbox"/>	<input type="checkbox"/>	WHOLE CARCASS DISPOSAL (Check one or more) <input checked="" type="checkbox"/> 1. Left at Site <input type="checkbox"/> 4. Rendered <input checked="" type="checkbox"/> 7. Unknown <input type="checkbox"/> 2. Buried <input type="checkbox"/> 5. Sunk <input type="checkbox"/> 3. Towed <input type="checkbox"/> 6. Frozen for Later Examination SPECIMEN DISPOSITION (Check one or more) <input type="checkbox"/> 1. Scientific Collection <input type="checkbox"/> 2. Educational Collection <input type="checkbox"/> 3. Other: _____ Comments: <u>not collected</u> _____ NECROPSIED <input type="checkbox"/> YES <input checked="" type="checkbox"/> NO Date: _____ NECROPSIED BY: _____
ID#	Color	Type	*Placement (Circle One)	Applied	Present																				
_____	_____	_____	D DF L LF LR RF RR	<input type="checkbox"/>	<input type="checkbox"/>																				
_____	_____	_____	D DF L LF LR RF RR	<input type="checkbox"/>	<input type="checkbox"/>																				
_____	_____	_____	D DF L LF LR RF RR	<input type="checkbox"/>	<input type="checkbox"/>																				

MARINE MAMMAL STRANDING REPORT - LEVEL A DATA

FIELD #: WIC 051303.SA NMFS REGIONAL #: 03NWR05010 NATIONAL DATABASE #: NW-2003-1000783
 COMMON NAME: HARBOUR PORPOISE GENUS: PHOCOENA SPECIES: PHOCOENA
 EXAMINER: _____ Letterholder: ARMY BIOLOGIST
 Name: _____ Affiliation: USA ISLAND COUNTY NMFSU
 Address: 1 COUDEVILLE WA 98237 Phone: _____

LOCATION State: <u>WA</u> County: <u>ISLAND</u> City: <u>COUDEVILLE</u> Locality Details: <u>FOOT CASEY STATE PARK ± 1/2 WAY BETW STRIP LINES AT POINT + GUN EMPLACEMENT</u> Latitude: <u>Admiralty Head</u> N Longitude: _____ W	OCCURRENCE DETAILS Mass Stranding: <input type="checkbox"/> YES <input checked="" type="checkbox"/> NO # Animals: _____ Signs of Human Interaction: <input type="checkbox"/> YES <input type="checkbox"/> NO <input checked="" type="checkbox"/> Could Not be Determined (CBD) (Check one or more) <input type="checkbox"/> 1. Boat Collision <input type="checkbox"/> 3. Fishery Interaction <input type="checkbox"/> 2. Shot <input checked="" type="checkbox"/> 4. Other Human Interaction: <u>POSSIBLE</u> How determined: <input checked="" type="checkbox"/> External Exam <input type="checkbox"/> Internal Exam <input type="checkbox"/> Not Examined Other Causes: <input type="checkbox"/> YES <input type="checkbox"/> NO <input type="checkbox"/> CBD Describe: _____
---	--

DATE OF INITIAL OBSERVATION Year: <u>2003</u> Month: <u>5</u> Day: <u>13</u> STATUS (Check ONE) <input type="checkbox"/> 1. Alive <input type="checkbox"/> 4. Advanced Decomposition <input checked="" type="checkbox"/> 2. Fresh Dead <input type="checkbox"/> 5. Mummified/Skeletal <input type="checkbox"/> 3. Moderate Decomposition <input type="checkbox"/> 6. Dead - Condition Unknown	DATE OF EXAMINATION (LEVEL A) <input type="checkbox"/> Not Able to Examine Year: <u>2003</u> Month: <u>5</u> Day: <u>13</u> CONDITION (Check ONE) <input type="checkbox"/> 1. Alive <input type="checkbox"/> 4. Advanced Decomposition <input checked="" type="checkbox"/> 2. Fresh Dead <input type="checkbox"/> 5. Mummified/Skeletal <input type="checkbox"/> 3. Moderate Decomposition <input type="checkbox"/> 6. Dead - Condition Unknown
--	--

INITIAL LIVE ANIMAL DISPOSITION (Check one or more) <input type="checkbox"/> 1. Left at Site <input type="checkbox"/> 5. Euthanized at Site <input type="checkbox"/> 2. Immediate Release at Site <input type="checkbox"/> 6. Died at Site <input type="checkbox"/> 3. Relocated <input type="checkbox"/> 7. Transferred to Rehabilitation <input type="checkbox"/> 4. Disentangled <input type="checkbox"/> 8. Died During Transport <input type="checkbox"/> 9. Other CONDITION (Check ONE) <input type="checkbox"/> 1. Sick <input type="checkbox"/> 3. Apparently Healthy <input type="checkbox"/> 5. Other <input type="checkbox"/> 2. Injured <input type="checkbox"/> 4. Out of Habitat Date: _____ Rehabilitation Facility: _____ Comments: _____	MORPHOLOGICAL DATA SEX (Check ONE) AGE CLASS (Check ONE) <input checked="" type="checkbox"/> 1. Male <input checked="" type="checkbox"/> 1. Adult <input type="checkbox"/> 4. Pup/Calf <input checked="" type="checkbox"/> 2. Female <input type="checkbox"/> 2. Subadult <input type="checkbox"/> 5. Unknown <input type="checkbox"/> 3. Unknown <input type="checkbox"/> 3. Yearling Straight Length: <u>154cm</u> <u>63"</u> <input type="checkbox"/> cm <input checked="" type="checkbox"/> in <input checked="" type="checkbox"/> actual <input type="checkbox"/> estimate Weight: <u>120</u> <input type="checkbox"/> kg <input checked="" type="checkbox"/> lb <input type="checkbox"/> actual <input checked="" type="checkbox"/> estimate PHOTOS/VIDEOS TAKEN: <input checked="" type="checkbox"/> YES <input type="checkbox"/> NO Disposition: <u>DIGITAL PHOTOS AVAILABLE ADMIRALTY HEAD LIGHTHOUSE. ALSO FROM RESPONDER</u>
---	--

TAG DATA <table border="1" style="width: 100%; border-collapse: collapse;"> <thead> <tr> <th>ID#</th> <th>Color</th> <th>Type</th> <th>*Placement (Circle One)</th> <th>Applied</th> <th>Present</th> </tr> </thead> <tbody> <tr> <td><u>0</u></td> <td></td> <td></td> <td>U DF L LF LR RF RR</td> <td><input type="checkbox"/></td> <td><input type="checkbox"/></td> </tr> <tr> <td></td> <td></td> <td></td> <td>D DF L LF LR RF RR</td> <td><input type="checkbox"/></td> <td><input type="checkbox"/></td> </tr> <tr> <td></td> <td></td> <td></td> <td>D DF L LF LR RF RR</td> <td><input type="checkbox"/></td> <td><input type="checkbox"/></td> </tr> </tbody> </table>	ID#	Color	Type	*Placement (Circle One)	Applied	Present	<u>0</u>			U DF L LF LR RF RR	<input type="checkbox"/>	<input type="checkbox"/>				D DF L LF LR RF RR	<input type="checkbox"/>	<input type="checkbox"/>				D DF L LF LR RF RR	<input type="checkbox"/>	<input type="checkbox"/>	WHOLE CARCASS DISPOSAL (Check one or more) <input type="checkbox"/> 1. Left at Site <input type="checkbox"/> 4. Rendered <input type="checkbox"/> 7. Unknown <input type="checkbox"/> 2. Buried <input type="checkbox"/> 5. Sunk <input type="checkbox"/> 3. Towed <input type="checkbox"/> 6. Frozen for Later Examination SPECIMEN DISPOSITION (Check one or more) <input checked="" type="checkbox"/> 1. Scientific Collection <input type="checkbox"/> 2. Educational Collection <input type="checkbox"/> 3. Other: _____ Comments: _____ NECROPSIED <input checked="" type="checkbox"/> YES <input type="checkbox"/> NO Date: <u>7/24/03</u> NECROPSIED BY: _____
ID#	Color	Type	*Placement (Circle One)	Applied	Present																				
<u>0</u>			U DF L LF LR RF RR	<input type="checkbox"/>	<input type="checkbox"/>																				
			D DF L LF LR RF RR	<input type="checkbox"/>	<input type="checkbox"/>																				
			D DF L LF LR RF RR	<input type="checkbox"/>	<input type="checkbox"/>																				

*D=Dorsal; DF=Dorsal Fin; L=Lateral Body
 LF=Left Front; LR=Left Rear; RF=Right Front; RR=Right Rear

6/23/03

ADDITIONAL REMARKS

03NW 205010

ADDITIONAL IDENTIFIER: _____

BEACH WATCHER COORDINATOR

WIC051303SD

Responder: _____, additional responder: _____

Initial report of stranded animal was made to SD by _____ Waste Wise Coordinator at approx. 10am at the Admiralty Head Lighthouse. She had spotted the carcass in the water during an early morning bird count.

Response approx. 10:30 am. Carcass was located approx 1/2 way between staircase at Fort Casey point and the beach access trail below the disappearing gun emplacement. The carcass was secured with a rope around the flukes and towed onto shore. It was identified as a 5'3" male harbor porpoise.

The carcass was fresh and very little superficial damage was observed on the skin. The skin was worn from the tips of the flukes, but the flesh intact. Skin coloration was evident. The carcass was bleeding from both eyes, with eye balls intact. There was leakage of blood from the blow hole when the head was turned. There was also a small amount of blood oozing from the mouth. The skull, jaws and teeth appeared to be intact.

Several researchers were notified via _____ of the Orca Network. _____ of the Marine Mammal Lab plans to come to Whidbey Island on Wed. evening, May 14, to retrieve the carcass.

SD returned to the site later in the afternoon of 5/13 and secured the carcass to driftwood. She again returned the next morning. Eagles had eaten a portion of the head and right side of the carcass. The left side was intact. SD wrapped the carcass in plastic and secured it with driftwood to protect it from further eagle damage. The shroud was labeled for pickup.

Park Rangers were notified of the location of the carcass and its impending pickup.

DISCLAIMER

These data should not be used out of context or without verification. This should be strictly enforced when reporting signs of human interaction data.

DATA ACCESS FOR LEVEL A DATA

Upon written request, certain fields of the Level A Data Sheet will be released to the requestor provided that the requestor credit the stranding network and the National Marine Fisheries Service. The National Marine Fisheries Service will notify the contributing stranding network members that these data have been requested and the intent of use. All other data will be released to the requestor provided that the requestor obtain permission from the contributing stranding network and the National Marine Fisheries Service.

PAPERWORK REDUCTION ACT INFORMATION

Public reporting burden for the collection of information is estimated to average 20 minutes per response, including the time for reviewing instructions, searching existing data sources, gathering and maintaining the data needed, and completing and reviewing the collection of information. Send comments regarding this burden estimate or any other aspect of the collection of information, including suggestions for reducing the burden to: Chief, Marine Mammal Conservation Division, Office of Protected Resources, NOAA Fisheries, 1315 East-West Highway, Silver Spring, Maryland 20910. Notwithstanding any other provision of the law, no person is required to respond to, nor shall any person be subjected to a penalty for failure to comply with, a collection of information subject to the requirements of the Paperwork Reduction Act, unless the collection of information displays a currently valid Office of Management and Budget (OMB) Control Number.



MARINE MAMMAL STRANDING REPORT - LEVEL A DATA

yes
to scan
7/20

FIELD #: OCNMS03 P 02 NMFS REGIONAL #: 03NWRO5011 NATIONAL DATABASE #: NW-2003-1000784

COMMON NAME: TURBO PORPOISE GENUS: PHOCOENA SPECIES: PHOCOENA

EXAMINER: _____ Letterholder: _____

Name: _____ Affiliation: OLYMPIC COAST NAT. MARINE SANCTUARY

Address: PORT ANGELES WA Phone: _____

LOCATION State: <u>WA</u> County: <u>CLALLAM</u> City: <u>PORT ANGELES</u> Locality Details: <u>EDIZ BROOK</u> <u>NORTH SIDE</u> <u>NEAR COAST GUARD GATE</u> Latitude: _____ N Longitude: _____ W	OCCURRENCE DETAILS Mass Stranding: <input type="checkbox"/> YES <input checked="" type="checkbox"/> NO # Animals: <u>1</u> Signs of Human Interaction: <input type="checkbox"/> YES <input checked="" type="checkbox"/> NO <input type="checkbox"/> Could Not be Determined (CBD) (Check one or more) <input type="checkbox"/> 1. Boat Collision <input type="checkbox"/> 2. Fishery Interaction <input type="checkbox"/> 2. Shot <input type="checkbox"/> 4. Other Human Interaction: _____ How determined: <input checked="" type="checkbox"/> External Exam <input type="checkbox"/> Internal Exam <input type="checkbox"/> Not Examined Other Causes: <input type="checkbox"/> YES <input type="checkbox"/> NO <input type="checkbox"/> CBD Describe: _____
--	--

DATE OF INITIAL OBSERVATION Year: <u>03</u> Month: <u>05</u> Day: <u>16</u> STATUS (Check ONE) <input type="checkbox"/> 1. Alive <input type="checkbox"/> 4. Advanced Decomposition <input checked="" type="checkbox"/> 2. Fresh Dead <input type="checkbox"/> 5. Mummified/Skeletal <input type="checkbox"/> 3. Moderate Decomposition <input type="checkbox"/> 6. Dead - Condition Unknown	DATE OF EXAMINATION (LEVEL A) <input type="checkbox"/> Not Able to Examine Year: _____ Month: _____ Day: _____ CONDITION (Check ONE) <input type="checkbox"/> 1. Alive <input type="checkbox"/> 4. Advanced Decomposition <input type="checkbox"/> 2. Fresh Dead <input type="checkbox"/> 5. Mummified/Skeletal <input type="checkbox"/> 3. Moderate Decomposition <input type="checkbox"/> 6. Dead - Condition Unknown
---	--

INITIAL LIVE ANIMAL DISPOSITION (Check one or more) <input type="checkbox"/> 1. Left at Site <input type="checkbox"/> 5. Euthanized at Site <input type="checkbox"/> 2. Immediate Release at Site <input type="checkbox"/> 6. Died at Site <input type="checkbox"/> 3. Relocated <input type="checkbox"/> 7. Transferred to Rehabilitation <input type="checkbox"/> 4. Disentangled <input type="checkbox"/> 8. Died During Transport <input type="checkbox"/> 8. Other CONDITION (Check ONE) <input type="checkbox"/> 1. Sick <input type="checkbox"/> 3. Apparently Healthy <input type="checkbox"/> 5. Other <input type="checkbox"/> 2. Injured <input type="checkbox"/> 4. Out of Habitat Date: _____ Rehabilitation Facility: _____ Comments: _____	MORPHOLOGICAL DATA SEX (Check ONE) AGE CLASS (Check ONE) <input type="checkbox"/> 1. Male <input checked="" type="checkbox"/> 1. Adult <input type="checkbox"/> 4. Pup/Calf <input checked="" type="checkbox"/> 2. Female <input type="checkbox"/> 2. Subadult <input type="checkbox"/> 5. Unknown <input type="checkbox"/> 3. Unknown <input type="checkbox"/> 3. Yearling Straight Length: <u>141</u> <input checked="" type="checkbox"/> cm <input type="checkbox"/> in <input type="checkbox"/> actual <input type="checkbox"/> estimate Weight: _____ <input type="checkbox"/> kg <input type="checkbox"/> lb <input type="checkbox"/> actual <input type="checkbox"/> estimate PHOTOS/VIDEOS TAKEN: <input checked="" type="checkbox"/> YES <input type="checkbox"/> NO Disposition: _____
---	---

TAG DATA <table border="1"> <thead> <tr> <th>ID#</th> <th>Color</th> <th>Type</th> <th>*Placement (Circle One)</th> <th>Applied</th> <th>Present</th> </tr> </thead> <tbody> <tr> <td></td> <td></td> <td></td> <td>D DF L</td> <td><input type="checkbox"/></td> <td><input type="checkbox"/></td> </tr> <tr> <td></td> <td></td> <td></td> <td>LF LR RF RR</td> <td><input type="checkbox"/></td> <td><input type="checkbox"/></td> </tr> <tr> <td></td> <td></td> <td></td> <td>D DF L</td> <td><input type="checkbox"/></td> <td><input type="checkbox"/></td> </tr> <tr> <td></td> <td></td> <td></td> <td>LF LR RF RR</td> <td><input type="checkbox"/></td> <td><input type="checkbox"/></td> </tr> <tr> <td></td> <td></td> <td></td> <td>D DF L</td> <td><input type="checkbox"/></td> <td><input type="checkbox"/></td> </tr> <tr> <td></td> <td></td> <td></td> <td>LF LR RF RR</td> <td><input type="checkbox"/></td> <td><input type="checkbox"/></td> </tr> </tbody> </table> <p>*D=Dorsal; DF=Dorsal Fin; L=Lateral Body LF=Left Front; LR=Left Rear; RF=Right Front; RR=Right Rear</p>	ID#	Color	Type	*Placement (Circle One)	Applied	Present				D DF L	<input type="checkbox"/>	<input type="checkbox"/>				LF LR RF RR	<input type="checkbox"/>	<input type="checkbox"/>				D DF L	<input type="checkbox"/>	<input type="checkbox"/>				LF LR RF RR	<input type="checkbox"/>	<input type="checkbox"/>				D DF L	<input type="checkbox"/>	<input type="checkbox"/>				LF LR RF RR	<input type="checkbox"/>	<input type="checkbox"/>	WHOLE CARCASS DISPOSAL (Check one or more) <input type="checkbox"/> 1. Left at Site <input type="checkbox"/> 4. Rendered <input type="checkbox"/> 7. Unknown <input type="checkbox"/> 2. Buried <input type="checkbox"/> 5. Sunk <input type="checkbox"/> 3. Towed <input checked="" type="checkbox"/> 6. Frozen for Later Examination SPECIMEN DISPOSITION (Check one or more) <input checked="" type="checkbox"/> 1. Scientific Collection <input type="checkbox"/> 2. Educational Collection <input type="checkbox"/> 3. Other: _____ Comments: _____ NECROPSIED <input checked="" type="checkbox"/> YES <input type="checkbox"/> NO Date: <u>7/23/03</u> NECROPSIED BY: _____
ID#	Color	Type	*Placement (Circle One)	Applied	Present																																						
			D DF L	<input type="checkbox"/>	<input type="checkbox"/>																																						
			LF LR RF RR	<input type="checkbox"/>	<input type="checkbox"/>																																						
			D DF L	<input type="checkbox"/>	<input type="checkbox"/>																																						
			LF LR RF RR	<input type="checkbox"/>	<input type="checkbox"/>																																						
			D DF L	<input type="checkbox"/>	<input type="checkbox"/>																																						
			LF LR RF RR	<input type="checkbox"/>	<input type="checkbox"/>																																						

6/23/03

ADDITIONAL REMARKS

ADDITIONAL IDENTIFIER: _____

LENGTH (CENTER OF FLUKE TO TIP OF SNOUT ALONG SIDE)

141 cm

- BLOOD Oozing FROM EYES, BLOWHOLE + MOUTH
- VENTRAL SIDE ** / MULTIPLE SCRAPS - PROBABLY GULL DAMAGE
- STRANDED HIGH ON INTERTIDAL

DISCLAIMER

These data should not be used out of context or without verification. This should be strictly enforced when reporting signs of human interaction data.

DATA ACCESS FOR LEVEL A DATA

Upon written request, certain fields of the Level A Data Sheet will be released to the requestor provided that the requestor credit the stranding network and the National Marine Fisheries Service. The National Marine Fisheries Service will notify the contributing stranding network members that these data have been requested and the intent of use. All other data will be released to the requestor provided that the requestor obtain permission from the contributing stranding network and the National Marine Fisheries Service.

PAPERWORK REDUCTION ACT INFORMATION

Public reporting burden for the collection of information is estimated to average 20 minutes per response, including the time for reviewing instructions, searching existing data sources, gathering and maintaining the data needed, and completing and reviewing the collection of information. Send comments regarding this burden estimate or any other aspect of the collection of information, including suggestions for reducing the burden to: Chief, Marine Mammal Conservation Division, Office of Protected Resources, NOAA Fisheries, 1315 East-West Highway, Silver Spring, Maryland 20910. Notwithstanding any other provision of the law, no person is required to respond to, nor shall any person be subjected to a penalty for failure to comply with, a collection of information subject to the requirements of the Paperwork Reduction Act, unless the collection of information displays a currently valid Office of Management and Budget (OMB) Control Number.



MARINE MAMMAL STRANDING REPORT - LEVEL A DATA

FIELD #: WIEGSTR035B NMFS REGIONAL #: 03NWRO5019 NATIONAL DATABASE #: NW-2003-1000819
 COMMON NAME: Harbor Porpoise GENUS: Phocoena SPECIES: phocoena
 EXAMINER: _____ Letterholder: _____
 Name: _____ Affiliation: Oke Network / Beach Watchers
 Address: _____ Phone: _____

LOCATION State: <u>WA</u> County: <u>Island</u> City: <u>Greenbank</u> Locality Details: <u>Lagoon Pt. on beach in front of 095 Westcliff Dr</u> Latitude: _____ N Longitude: _____ W	OCCURRENCE DETAILS Mass Stranding: <input type="checkbox"/> YES <input checked="" type="checkbox"/> NO # Animals: _____ Signs of Human Interaction: <input type="checkbox"/> YES <input checked="" type="checkbox"/> NO <input type="checkbox"/> Could Not be Determined (CND) (Check one or more) <input type="checkbox"/> 1. Boat Collision <input type="checkbox"/> 3. Fishery Interaction <input type="checkbox"/> 2. Shot <input type="checkbox"/> 4. Other Human Interaction: _____ How determined: <input checked="" type="checkbox"/> External Exam <input type="checkbox"/> Internal Exam <input type="checkbox"/> Not Examined Other Causes: <input type="checkbox"/> YES <input type="checkbox"/> NO <input type="checkbox"/> CBD Describe: _____
---	---

DATE OF INITIAL OBSERVATION Year: <u>03</u> Month: <u>05</u> Day: <u>17</u> STATUS (Check ONE) <input type="checkbox"/> 1. Alive <input type="checkbox"/> 4. Advanced Decomposition <input checked="" type="checkbox"/> 2. Fresh Dead <input type="checkbox"/> 5. Mummified/Skeletal <input type="checkbox"/> 3. Moderate Decomposition <input type="checkbox"/> 6. Dead - Condition Unknown	DATE OF EXAMINATION (LEVEL A) <input type="checkbox"/> Not Able to Examine Year: <u>03</u> Month: <u>05</u> Day: <u>17</u> CONDITION (Check ONE) <input type="checkbox"/> 1. Alive <input type="checkbox"/> 4. Advanced Decomposition <input checked="" type="checkbox"/> 2. Fresh Dead <input type="checkbox"/> 5. Mummified/Skeletal <input type="checkbox"/> 3. Moderate Decomposition <input type="checkbox"/> 6. Dead - Condition Unknown
---	---

INITIAL LIVE ANIMAL DISPOSITION (Check one or more) <input type="checkbox"/> 1. Left at Site <input type="checkbox"/> 5. Euthanized at Site <input type="checkbox"/> 2. Immediate Release at Site <input type="checkbox"/> 6. Died at Site <input type="checkbox"/> 3. Relocated <input type="checkbox"/> 7. Transferred to Rehabilitation <input type="checkbox"/> 4. Disentangled <input type="checkbox"/> 8. Died During Transport <input type="checkbox"/> 9. Other CONDITION (Check ONE) <input type="checkbox"/> 1. Sick <input type="checkbox"/> 3. Apparently Healthy <input type="checkbox"/> 5. Other <input type="checkbox"/> 2. Injured <input type="checkbox"/> 4. Out of Habitat Date: _____ Rehabilitation Facility: _____ Comments: _____	MORPHOLOGICAL DATA SEX (Check ONE) AGE CLASS (Check ONE) <input type="checkbox"/> 1. Male <input checked="" type="checkbox"/> 1. Adult <input type="checkbox"/> 4. Pup/Calf <input checked="" type="checkbox"/> 2. Female <input type="checkbox"/> 2. Subadult <input type="checkbox"/> 5. Unknown <input type="checkbox"/> 3. Unknown <input type="checkbox"/> 3. Yearling Straight Length: <u>138 cm</u> <input type="checkbox"/> cm <input checked="" type="checkbox"/> in <input checked="" type="checkbox"/> actual <input type="checkbox"/> estimate Weight: <u>54</u> <input type="checkbox"/> kg <input type="checkbox"/> lb <input type="checkbox"/> actual <input type="checkbox"/> estimate PHOTOS/VIDEOS TAKEN: <input checked="" type="checkbox"/> YES <input type="checkbox"/> NO <i>digital photos & video</i> Disposition: <u>picked up specimen the evening of 5/17/03, brought to NMML for further examination</u>
---	---

TAG DATA <table style="width: 100%; border-collapse: collapse;"> <thead> <tr> <th>ID#</th> <th>Color</th> <th>Type</th> <th>*Placement (Circle One)</th> <th>Applied</th> <th>Present</th> </tr> </thead> <tbody> <tr> <td></td> <td></td> <td></td> <td>D DF L LF LR RF RR</td> <td style="text-align: center;"><input type="checkbox"/></td> <td style="text-align: center;"><input type="checkbox"/></td> </tr> <tr> <td></td> <td></td> <td></td> <td>D DF L LF LR RF RR</td> <td style="text-align: center;"><input type="checkbox"/></td> <td style="text-align: center;"><input type="checkbox"/></td> </tr> <tr> <td></td> <td></td> <td></td> <td>D DF L LF LR RF RR</td> <td style="text-align: center;"><input type="checkbox"/></td> <td style="text-align: center;"><input type="checkbox"/></td> </tr> </tbody> </table> <p>*D=Dorsal; DF=Dorsal Fin; L=Lateral Body LF=Left Front; LR=Left Rear; RF=Right Front; RR=Right Rear</p>	ID#	Color	Type	*Placement (Circle One)	Applied	Present				D DF L LF LR RF RR	<input type="checkbox"/>	<input type="checkbox"/>				D DF L LF LR RF RR	<input type="checkbox"/>	<input type="checkbox"/>				D DF L LF LR RF RR	<input type="checkbox"/>	<input type="checkbox"/>	WHOLE CARCASS DISPOSAL (Check one or more) <input type="checkbox"/> 1. Left at Site <input type="checkbox"/> 4. Rendered <input type="checkbox"/> 7. Unknown <input type="checkbox"/> 2. Buried <input type="checkbox"/> 5. Sunk <input type="checkbox"/> 3. Towed <input type="checkbox"/> 6. Frozen for Later Examination SPECIMEN DISPOSITION (Check one or more) <input checked="" type="checkbox"/> 1. Scientific Collection <input type="checkbox"/> 2. Educational Collection <input type="checkbox"/> 3. Other: _____ Comments: <u>Brought to NMML by other recent porpoise specimens to be necropsied with</u> NECROPSIED <input checked="" type="checkbox"/> YES <input type="checkbox"/> NO Date: <u>7/24/03</u> NECROPSIED BY: _____
ID#	Color	Type	*Placement (Circle One)	Applied	Present																				
			D DF L LF LR RF RR	<input type="checkbox"/>	<input type="checkbox"/>																				
			D DF L LF LR RF RR	<input type="checkbox"/>	<input type="checkbox"/>																				
			D DF L LF LR RF RR	<input type="checkbox"/>	<input type="checkbox"/>																				

6/30/03

ADDITIONAL IDENTIFIER: _____

The call came in at 8³⁰ am, I responded at approx. 10 am. No visible cause of death, freshly dead specimen. Was called to collect specimen, due to high number of porpoise strandings + coincident Naval sonar exercises. After measuring + examination, we wrapped the specimen in a tarp to protect from predation by eagles, + moved it above the high tide line. Picked it up that evening.

DISCLAIMER

These data should not be used out of context or without verification. This should be strictly enforced when reporting signs of human interaction data.

DATA ACCESS FOR LEVEL A DATA

Upon written request, certain fields of the Level A Data Sheet will be released to the requestor provided that the requestor credit the stranding network and the National Marine Fisheries Service. The National Marine Fisheries Service will notify the contributing stranding network members that these data have been requested and the intent of use. All other data will be released to the requestor provided that the requestor obtain permission from the contributing stranding network and the National Marine Fisheries Service.

PAPERWORK REDUCTION ACT INFORMATION

Public reporting burden for the collection of information is estimated to average 20 minutes per response, including the time for reviewing instructions, searching existing data sources, gathering and maintaining the data needed, and completing and reviewing the collection of information. Send comments regarding this burden estimate or any other aspect of the collection of information, including suggestions for reducing the burden to: Chief, Marine Mammal Conservation Division, Office of Protected Resources, NOAA Fisheries, 1315 East-West Highway, Silver Spring, Maryland 20910. Notwithstanding any other provision of the law, no person is required to respond to, nor shall any person be subjected to a penalty for failure to comply with, a collection of information subject to the requirements of the Paperwork Reduction Act, unless the collection of information displays a currently valid Office of Management and Budget (OMB) Control Number.



MARINE MAMMAL STRANDING REPORT

NW 2003-1000785

SID# (NMFS USE)

FIELD NO.: 2003-SJ009 NMFS REGISTRATION NO.: 03NWRO5012
 COMMON NAME: Harbor Porpoise GENUS: Phocoena SPECIES: phocoena
 EXAMINER: _____ Agency: The Whale Museum Phone: _____
 Name: _____ Friday Harbor WA 98250

To scan 7/1/03

LOCATION State: <u>WA</u> County: <u>San Juan</u> City: _____ Locality Details: <u>Eagle Pt., West side San Juan Island</u> <u>Floating</u> *Latitude: _____ N *Longitude: _____ W	TYPE OF OCCURRENCE Mass Stranding: <input type="checkbox"/> Yes <input checked="" type="checkbox"/> No # Animals <u>1</u> Human Interaction: <input type="checkbox"/> Yes <input type="checkbox"/> No <input checked="" type="checkbox"/> ? Check one: <input type="checkbox"/> 1. Boat Collision <input type="checkbox"/> 2. Shot <input type="checkbox"/> 3. Fishery Interaction <input type="checkbox"/> 4. Other _____ How determined: _____ Other Causes (if known): _____
---	---

DATE OF INITIAL OBSERVATION: Yr. <u>2003</u> Mo. <u>5</u> Day <u>20</u> CONDITION: Check one: <input type="checkbox"/> 1. Alive <input checked="" type="checkbox"/> 2. Fresh dead <input type="checkbox"/> 3. Moderate decomp. <input type="checkbox"/> 4. Advanced decomp. <input type="checkbox"/> 5. Mummified <input type="checkbox"/> ? Unknown	DATE OF EXAMINATION: Yr. <u>2003</u> Mo. <u>5</u> Day <u>20</u> CONDITION: Check one: <input type="checkbox"/> 1. Alive <input checked="" type="checkbox"/> 2. Fresh dead <input type="checkbox"/> 3. Moderate decomp. <input type="checkbox"/> 4. Advanced decomp. <input type="checkbox"/> 5. Mummified <input type="checkbox"/> ? Unknown
---	---

LIVE ANIMAL — Condition and Disposition: Check one or more: <input type="checkbox"/> 1. Released at site <input type="checkbox"/> 2. Sick <input type="checkbox"/> 3. Injured <input type="checkbox"/> 4. Died <input type="checkbox"/> 5. Euthanized <input type="checkbox"/> 6. Rehabilitated and released <input type="checkbox"/> ? Unknown Transported to: _____ <input type="checkbox"/> Died <input type="checkbox"/> Released Date: _____	TAGS APPLIED?: <input type="checkbox"/> Yes <input checked="" type="checkbox"/> No TAGS PRESENT?: <input type="checkbox"/> Yes <input checked="" type="checkbox"/> No <table style="width: 100%; text-align: center;"> <tr> <td></td> <td>Dorsal</td> <td>Left</td> <td>Right</td> </tr> <tr> <td>Tag No.(s):</td> <td>_____</td> <td>_____</td> <td>_____</td> </tr> <tr> <td>Color(s):</td> <td>_____</td> <td>_____</td> <td>_____</td> </tr> <tr> <td>Type:</td> <td>_____</td> <td>_____</td> <td>_____</td> </tr> <tr> <td>Placement</td> <td></td> <td>Front/Rear</td> <td>Front/Rear</td> </tr> </table>		Dorsal	Left	Right	Tag No.(s):	_____	_____	_____	Color(s):	_____	_____	_____	Type:	_____	_____	_____	Placement		Front/Rear	Front/Rear
	Dorsal	Left	Right																		
Tag No.(s):	_____	_____	_____																		
Color(s):	_____	_____	_____																		
Type:	_____	_____	_____																		
Placement		Front/Rear	Front/Rear																		

CARCASS — Disposition: Check one: <input type="checkbox"/> 1. Left at site <input type="checkbox"/> 2. Buried <input type="checkbox"/> 3. Towed <input checked="" type="checkbox"/> 4. Sci. collection: (see below) <input type="checkbox"/> 5. Edu. collection: (see below) <input type="checkbox"/> 6. Other _____ <input type="checkbox"/> ? Unknown NECROPSIED? <u>7/23/03</u> <input checked="" type="checkbox"/> Yes <input type="checkbox"/> No	MORPHOLOGICAL DATA: Sex — Check one: <input checked="" type="checkbox"/> 1. Male <input type="checkbox"/> 2. Female <input type="checkbox"/> ? Unknown Contour: Straight Length: <u>123</u> cm <input type="checkbox"/> in <input type="checkbox"/> est *Weight _____ <input type="checkbox"/> lb <input type="checkbox"/> est PHOTOS TAKEN? <input checked="" type="checkbox"/> Yes <input type="checkbox"/> No Girth _____ in _____ est
--	---

REMARKS: Towed by whale-watch operator to Snug Harbor, picked up animal and stored it in Center for Whale Research (CWR) freezer

DISPOSITION OF TISSUE/SKELETAL MATERIAL: _____

6/23/03

MARINE MAMMAL STRANDING REPORT - LEVEL A DATA

the copy 7/22

1 21 *LT done*

FIELD #: CRC 490 NMFS REGIONAL #: 03NWRO6005 NATIONAL DATABASE #: NW-2003-100106
(NMFS USE) (NMFS USE)

COMMON NAME: Harbor Porpoise GENUS: P. SPECIES: phocoena

EXAMINER: _____ Letterholder: _____

Name: Cascadia Research Affiliation: _____

Address: _____ Phone: _____

LOCATION State: <u>WA</u> County: <u>Pacific</u> City: <u>Long Beach</u> Locality Details: _____ Latitude: _____ N Longitude: _____ W	OCCURRENCE DETAILS Mass Stranding: <input type="checkbox"/> YES <input type="checkbox"/> NO # Animals: <u>1</u> Signs of Human Interaction: <input type="checkbox"/> YES <input checked="" type="checkbox"/> NO <input checked="" type="checkbox"/> Could Not be Determined (CBD) (Check one or more) <input type="checkbox"/> 1. Boat Collision <input type="checkbox"/> 3. Fishery Interaction <input type="checkbox"/> 2. Shot <input type="checkbox"/> 4. Other Human Interaction: _____ How determined: <input checked="" type="checkbox"/> External Exam <input type="checkbox"/> Internal Exam <input type="checkbox"/> Not Examined Other Causes: <input type="checkbox"/> YES <input type="checkbox"/> NO <input checked="" type="checkbox"/> CBD Describe: _____
---	---

DATE OF INITIAL OBSERVATION Year: <u>03</u> Month: <u>06</u> Day: <u>02</u> STATUS (Check ONE) <input type="checkbox"/> 1. Alive <input type="checkbox"/> 4. Advanced Decomposition <input checked="" type="checkbox"/> 2. Fresh Dead <input type="checkbox"/> 5. Mummified/Skeletal <input type="checkbox"/> 3. Moderate Decomposition <input type="checkbox"/> 6. Dead - Condition Unknown	DATE OF EXAMINATION (LEVEL A) <input type="checkbox"/> Not Able to Examine Year: <u>03</u> Month: <u>06</u> Day: <u>02</u> CONDITION (Check ONE) <input type="checkbox"/> 1. Alive <input type="checkbox"/> 4. Advanced Decomposition <input checked="" type="checkbox"/> 2. Fresh Dead <input type="checkbox"/> 5. Mummified/Skeletal <input type="checkbox"/> 3. Moderate Decomposition <input type="checkbox"/> 6. Dead - Condition Unknown
---	---

INITIAL LIVE ANIMAL DISPOSITION (Check one or more) <input type="checkbox"/> 1. Left at Site <input type="checkbox"/> 5. Euthanized at Site <input type="checkbox"/> 2. Immediate Release at Site <input type="checkbox"/> 6. Died at Site <input type="checkbox"/> 3. Relocated <input type="checkbox"/> 7. Transferred to Rehabilitation <input type="checkbox"/> 4. Disentangled <input type="checkbox"/> 8. Died During Transport <input type="checkbox"/> 9. Other CONDITION (Check ONE) <input type="checkbox"/> 1. Sick <input type="checkbox"/> 3. Apparently Healthy <input type="checkbox"/> 5. Other <input type="checkbox"/> 2. Injured <input type="checkbox"/> 4. Out of Habitat Date: _____ Rehabilitation Facility: _____ Comments: _____	MORPHOLOGICAL DATA SEX (Check ONE) AGE CLASS (Check ONE) <input checked="" type="checkbox"/> 1. Male <input type="checkbox"/> 1. Adult <input type="checkbox"/> 4. Pup/Calf <input type="checkbox"/> 2. Female <input checked="" type="checkbox"/> 2. Subadult <input type="checkbox"/> 5. Unknown <input type="checkbox"/> 3. Unknown <input type="checkbox"/> 3. Yearling Straight Length: <u>141</u> <input checked="" type="checkbox"/> cm <input type="checkbox"/> in <input checked="" type="checkbox"/> actual <input type="checkbox"/> estimate Weight: _____ <input type="checkbox"/> kg <input type="checkbox"/> lb <input type="checkbox"/> actual <input type="checkbox"/> estimate PHOTOS/VIDEOS TAKEN: <input checked="" type="checkbox"/> YES <input type="checkbox"/> NO Disposition: <u>NWR office</u>
---	---

TAG DATA <table style="width: 100%; border-collapse: collapse;"> <thead> <tr> <th>ID#</th> <th>Color</th> <th>Type</th> <th>*Placement (Circle One)</th> <th>Applied</th> <th>Present</th> </tr> </thead> <tbody> <tr> <td>_____</td> <td></td> <td></td> <td>D DF L LF LR RF RR</td> <td style="text-align: center;"><input type="checkbox"/></td> <td style="text-align: center;"><input type="checkbox"/></td> </tr> <tr> <td>_____</td> <td></td> <td></td> <td>D DF L LF LR RF RR</td> <td style="text-align: center;"><input type="checkbox"/></td> <td style="text-align: center;"><input type="checkbox"/></td> </tr> <tr> <td>_____</td> <td></td> <td></td> <td>D DF L LF LR RF RR</td> <td style="text-align: center;"><input type="checkbox"/></td> <td style="text-align: center;"><input type="checkbox"/></td> </tr> </tbody> </table> <p><small>*D=Dorsal; DF=Dorsal Fin; L=Lateral Body LF=Left Front; LR=Left Rear; RF=Right Front; RR=Right Rear</small></p>	ID#	Color	Type	*Placement (Circle One)	Applied	Present	_____			D DF L LF LR RF RR	<input type="checkbox"/>	<input type="checkbox"/>	_____			D DF L LF LR RF RR	<input type="checkbox"/>	<input type="checkbox"/>	_____			D DF L LF LR RF RR	<input type="checkbox"/>	<input type="checkbox"/>	WHOLE CARCASS DISPOSAL (Check one or more) <input type="checkbox"/> 1. Left at Site <input type="checkbox"/> 4. Rendered <input type="checkbox"/> 7. Unknown <input type="checkbox"/> 2. Buried <input type="checkbox"/> 5. Sunk <input type="checkbox"/> 3. Towed <input checked="" type="checkbox"/> 6. Frozen for Later Examination SPECIMEN DISPOSITION (Check one or more) <input checked="" type="checkbox"/> 1. Scientific Collection <input type="checkbox"/> 2. Educational Collection <input type="checkbox"/> 3. Other: _____ Comments: _____ NECROPSIED <input checked="" type="checkbox"/> YES <input type="checkbox"/> NO Date: <u>7/22/03</u> NECROPSIED BY: _____
ID#	Color	Type	*Placement (Circle One)	Applied	Present																				
_____			D DF L LF LR RF RR	<input type="checkbox"/>	<input type="checkbox"/>																				
_____			D DF L LF LR RF RR	<input type="checkbox"/>	<input type="checkbox"/>																				
_____			D DF L LF LR RF RR	<input type="checkbox"/>	<input type="checkbox"/>																				

Appendix B. Phocoenid strandings in British Columbia, Canada (April - May 2003)

Date of Initial Observation	Location	Case Number	Species	Gender	Comments
4/22/2003	Clover Point	2767	Harbor porpoise	M	head and limbs amputated; NSF
4/29/2003	Willow Beach	2768	Dall's porpoise	M	cryptococcosis
5/1/03	Esquimalt, Vancouver Island, BC	2769	Harbor porpoise	M	fetus, marked meconium aspiration
5/2/03	Seabird Point, Discovery Island, BC	03NWR05032	Harbor porpoise	U	not collected
5/21/03	Bamfield, Vancouver Island, BC	2770	Dall's porpoise	F	cryptococcosis

Appendix C. Investigation team members with affiliations and expertise.

Investigation Team Leaders -

William A. McLellan

University of North Carolina, Wilmington
601 S. College Dr.
Wilmington, NC 28403

Bill is a Research Scientist at the University of North Carolina at Wilmington. Mr. McLellan is the North Carolina State Stranding Coordinator and the Large Whale Mortality Team Leader for the mid-Atlantic and recently received the NOAA Environmental Hero Award in recognition of outstanding efforts to respond and investigate stranded marine mammals throughout the nation.

Ann Pabst

University of North Carolina, Wilmington
601 S. College Dr.
Wilmington, NC 28403

Dr. Pabst is a Professor in Biological Sciences at the University of North Carolina at Wilmington. Her work on the bio-mechanics of small cetacean skin and blubber combines the principles of mechanical engineering with the study of organismal form and function using quantitative morphological techniques, image analysis, and mechanical tests. Both McLellan and Pabst have over 20 years of experience working with dead stranded and live cetaceans. Harbor porpoises have been a focal species for this team - they have necropsied over 250 porpoises during their research. Their current focus, on the functional morphology of cetaceans is specific to locomotion and thermoregulation but extends also to the functional development of muscle, skeleton and skin.

Darlene Ketten

Biology Department
Woods Hole Oceanographic Institution
Woods Hole MA 02543 USA

Dr. Ketten is a marine biologist and neuroanatomist specializing in how behavior is linked to sensory system structure and function. She holds joint appointments as a senior scientist in the biology department of Woods Hole Oceanographic Institution and as assistant professor in Otolaryngology at Harvard Medical School. Her current work focuses on underwater sound reception and hearing mechanisms of marine mammals and research on the diagnostic and mechanistic analysis of pathology, trauma and disease of the ears and ear region. In addition to basic research, Dr. Ketten provides specialty forensic analyses of the head and neck for NOAA Fisheries investigations in stranded animals. Dr. Ketten has served on federal advisory boards and panels on hearing, bioacoustics, acoustic trauma, cochlear implant policy and procedures, marine mammal acoustics and ocean noise for the National Institute of Health, National Institutes of Deafness and Communication Disorders, NIH Consensus Development Conferences, the National Academy of Sciences, the Marine Mammal Commission, Minerals Management Service, NATO, Office of Naval Research and NOAA Fisheries.

Appendix C. Investigation team members with affiliations and expertise.

Additional team members-

Stephen Raverty

Ministry of Agriculture Food and Fisheries
1767 Angus Campbell Rd.
Abbotsford, British Columbia
V3G 2M3
Canada

Dr. Raverty is a board-certified, veterinary pathologist with the Ministry of Agriculture, Food and Fisheries in Abbotsford, British Columbia and over the last 5 years has participated in the post mortem examination and disease outbreak investigations of stranded marine mammals off the coast of British Columbia and more recently within Washington state.

Michelle Fleetwood

Armed Forces Institute of Pathology
6825 16th St. NW
Washington, DC 20306

Dr. Fleetwood, DVM, Chief, Consultation Branch, Department of Veterinary Pathology, Armed Forces Institute of Pathology. She is a Diplomate of the American College of Veterinary Pathologists.

Joseph K. Gaydos

SeaDoc Society
UC Davis Wildlife Health Center
982 Deer Harbor Rd.
Eastsound, WA 98245

Dr. Gaydos is a wildlife veterinarian and the staff scientist for the SeaDoc Society (UC Davis Wildlife Health Center). He is a veterinarian and has a PhD in wildlife diseases. He resides on Orcas Island, Washington State and has worked with Rich Osborne of the Whale Museum for the past year on a project determining the causes of death for stranded marine mammals in San Juan County, Washington.

Steve Jeffries

Washington Department of Fish and Wildlife
Marine Mammal Program
7801 Phillips Rd. SW
Tacoma, WA 98498

Mr. Jeffries is a Research Scientist with State of Washington Department of Fish and Wildlife's Marine Mammal Investigation unit. Primary response center for Northwest Marine Mammal Stranding Network. Extensive experience with examining marine mammals from regional

Appendix C. Investigation team members with affiliations and expertise.

fishery bycatch and strandings in Northwest. Primary response center for marine mammal strandings in Washington since 1980.

Tara Cox

Marine Mammal Commission
4340 East-West Highway, Room 905
Bethesda, MD 20814

Dr. Cox is Assistant Scientific Program Director, Marine Mammal Commission

Dyanna Lambourn

Washington Department of Fish and Wildlife
Marine Mammal Program
7801 Phillips Rd. SW
Tacoma, WA 98498

Ms. Lambourn is a Wildlife Biologist with the Marine Mammal Investigation Program of the Washington Department of Fish and Wildlife.

Brad Hanson

Northwest Fisheries Science Center
2725 Montlake Blvd. East
Seattle, WA 98112-2097

Dr. Hanson is a biologist with the Marine Mammal Program, Northwest Fisheries Science Center, NOAA Fisheries.

Brent Norberg

Lynne Barre

Stephanie Norman

NOAA/NMFS
NWR/Protected Resources Division
7600 Sand Point Way, NE
Building 1
Seattle, WA 98115

Mr. Norberg is the Northwest Regional Marine Mammal Stranding Coordinator with the Protected Resources Division, Northwest Regional Office, NOAA Fisheries.

Ms. Barre is a Marine Mammal Specialist with the Protected Resources Division, Northwest Regional Office, NOAA Fisheries.

Appendix C. Investigation team members with affiliations and expertise.

Dr. Norman is a Marine Mammal Veterinarian with the Protected Resources Division, Northwest Regional Office, NOAA Fisheries.

Scott Cramer

Biology Department
Woods Hole Oceanographic Institution
Woods Hole MA 02543 USA

Mr. Cramer is a research assistant in Dr. Ketten's laboratory.

Appendix D. List of harbor porpoise (*Phocoena phocoena*) stranding events in Washington State 1992-2002.

Initial Date	City	State	Field ID Number	Number of Animals	Sex	Length (cm)	Examiner
5/14/1992	La Push	WA	RCF282	1	M	89	National Marine Mammal Lab (NMML)
5/26/1992	Neah Bay	WA	RCF 284	2	M	133	NMML
7/5/1992	Long Beach	WA	HP92-07-05	1	M	75*	Marine Animal Resource Center (MARC)
8/22/1992	La Conner	WA	HP92-08-22	1	M	136	MARC
10/4/1992	Long Beach peninsula	WA	RLH 005	1	M	155	NMML
10/4/1992	Long Beach peninsula	WA	RLH 013	1	M	147	NMML
10/4/1992	Long Beach peninsula	WA	KMM 043	1	M	144	NMML
10/4/1992	Long Beach peninsula	WA	KMM 049	1	M	152	NMML
10/9/1992	Long Beach peninsula	WA	JCC 002	1	M	144	NMML
10/23/1992	Squaxin Island	WA	JCC-004	1	M		Public
1/30/1993	Belfair	WA	HP93-01-30	1	M	181	MARC
2/14/1993	Moclips	WA	MARC93-022	1	U	120*	MARC
4/5/1993	San Juan Island	WA	PJG-126	1	M	153	NMML
5/2/1993	Lopez Island	WA		1	M	130*	Whale Museum
5/21/1993	Port Angeles	WA	SDO-93-010	1	M	133	NMML

* - estimated length

Appendix D. List of harbor porpoise (*Phocoena phocoena*) stranding events in Washington State 1992-2002.

Initial Date	City	State	Field ID Number	Number of Animals	Sex	Length (cm)	Examiner
6/17/1993	Ocean Shores	WA		1	U	120*	Public
8/21/1993	Brown Island	WA	PJG-130	1	U	105*	NMML
9/22/1993	Tacoma	WA	MARC93-279	1	F	94*	MARC
5/2/1994	San Juan Island	WA		1	M	125	Whale Museum
7/25/1994	San Juan Island	WA	SJ078-94	1	F	80	Whale Museum
8/1/1994	San Juan Island	WA	SJ099-94	1	U		Whale Museum
8/3/1994	Lopez Island	WA	SJ100-94	1	F		Whale Museum
4/17/1995	Orcas Island	WA	SJ-002-95	1	M	135	Whale Museum
4/19/1995	Lopez Island	WA	SJ003-95	2	F	178	Whale Museum
8/20/1995	Orcas Island	WA	SJ045-95	1	F	75	Whale Museum
10/24/1995	San Juan Island	WA	SJ066-95	1	F	107.5	Whale Museum
10/29/1995	San Juan Island	WA	SJ067-95	1	U	92.5	Whale Museum
5/11/1997	San Juan Island	WA	SJ017-97	1	U	135*	Whale Museum
9/14/1997	San Juan Island	WA	SJ096-97	1	U	135*	Public
4/8/1998	Anacortes	WA		1	M	127	NMML
4/30/1998	Shaw Is.	WA		1	U	0	Public
7/17/1998	Waldron Island	WA		1	U	50*	U.S. Coast Guard
8/8/1998	San Juan Island	WA	1998-SJ015	1	F	90*	Whale Museum
11/22/1998	San Juan Island	WA		1	F	177.5*	Whale Museum
3/11/1999	Pt. Roberts	WA	MBHPp99001	1	M	44*	Public
5/21/1999	Friday Harbor	WA	1999-SJ005	1	M	152	Whale Museum

* - estimated length

Appendix D. List of harbor porpoise (*Phocoena phocoena*) stranding events in Washington State 1992-2002.

Initial Date	City	State	Field ID Number	Number of Animals	Sex	Length (cm)	Examiner
1/29/2000	San Juan Island	WA	2000SJO01	1	F	140*	Whale Museum
3/17/2000	Ocean Shores	WA	MMP00-10	1	F	176	Washington Department of Fish and Wildlife
3/29/2000	Lopez Island	WA	2000-SJ017	1	U	107.5	Whale Museum
4/14/2000	San Juan Island	WA	2000SJ007	1	U		Public
8/12/2000	Rialto Beach	WA	MBHPp20001	1	M	116	Park Ranger
8/29/2000	Bellingham	WA		1	F	143	NMFS Enforcement
1/7/2001	Port Angeles	WA	Dng-01-002	1	M	155	National Marine Fisheries Service (NMFS)
4/27/2001	Strait of Juan de Fuca	WA	001-01	1	F	132.5	M. Klope
5/2/2001	Lopez Island	WA	2001-SJ002	1	F	142.5	Whale Museum
5/2/2001	Port Townsend	WA		1	U	120*	NMML
5/3/2001	San Juan Island	WA	2001-SJ003	1	F	130	Whale Museum
5/10/2001	San Juan Island	WA	2001-SJ004	1	F	135*	Whale Museum
5/13/2001	Sequim	WA	Dng-01-004	1	F	1010	NMML
5/17/2001	Port Angeles	WA		1	M	135	NMML
5/26/2001	San Juan Island	WA	2001-SJ005	1	U		Whale Museum
7/9/2001	Mountain View	WA		1	U	135*	NMFS Enforcement
7/12/2001	Ocean Shores	WA	CRC - 478	1	M	85	Cascadia Research
7/31/2001	San Juan Island	WA	2001-SJ041	1	F	155	Whale Museum

* - estimated length

Appendix D. List of harbor porpoise (*Phocoena phocoena*) stranding events in Washington State 1992-2002.

Initial Date	City	State	Field ID Number	Number of Animals	Sex	Length (cm)	Examiner
8/16/2001	Port Townsend	WA		1	U	75*	Olympic Coast National Marine Sanctuary (OCNMS)
12/25/2001	Orcas Island	WA	2001-SJ059	1	M	117.5	Whale Museum
12/27/2001	Shaw Island	WA	2001-SJ060	1	M	132	Whale Museum
1/15/2002	Whidbey Island	WA	001-02	1	U		M. Klope
3/12/2002	Port Angeles	WA		1	M	130	OCNMS
4/27/2002	Samish Island	WA		1	M	128	NMML
5/15/2002	San Juan Island	WA	2002-SJ004	1	F	165	Whale Museum
5/30/2002	Lopez Island	WA	2002-SJ033	1	M	146	Whale Museum
6/15/2002	Lopez Island	WA	2002-SJ006	1	M	162.5	Whale Museum
6/16/2002	Crescent Bay	WA		1	M	132.5	Public
8/6/2002	Shaw Island	WA	2002-SJ025	1	U	97.5*	Whale Museum
8/25/2002	Point Roberts	WA	01/03278	1	F	172	S. Raverty

* - estimated length

Appendix E. Marine Mammal stranding events reported in Washington State April-June 2003

Initial Date	Species	Number Animals	City	State	Field ID Number	Registration Number	Sex	Length (cm)	Examiner
4/2/2003	HARBOR SEAL	1	Belfair	WA	03-MA-009	03NWR04001	U	N/E	Public
4/8/2003	HARBOR SEAL	1	Bainbridge Island	WA	03-KP-010	03NWR04002	U	122	Public
4/11/2003	HARBOR SEAL	1	Vashon Island	WA	03-KG-012	03NWR04004	U	152	Public
4/14/2003	HARBOR SEAL	1	Kingston	WA	03-KP-011	03NWR04003	U	91	Public
4/14/2003	HARBOR SEAL	1	San Juan Island	WA	2003-SJ004	03NWR04007	U	N/E	Whale Museum
4/16/2003	UNSPECIFIED SEA LION	1	Ocean Park	WA	03-PA-014	03NWR04008	M	198	Public
4/19/2003	HARBOR PORPOISE	1	South Sand Point	WA	03-CM-015	03NWR04009	U	N/E	National Park Service
4/21/2003	UNSPECIFIED SEA LION	1	County Line Park	WA	03-WA-013	03NWR04006	U	N/E	Public
4/23/2003	CALIFORNIA SEA LION	1	Sucia Island	WA	2003-SJ005	03NWR04010	M	N/E	Whale Museum
4/26/2003	HARBOR SEAL	2	Ocean Shores	WA	03-GH-016	03NWR04011	F	122	Public
5/2/2003	HARBOR PORPOISE	1	Shaw Island	WA	2003-SJ006	03NWR05001	F	136	Whale Museum
5/3/2003	CALIFORNIA SEA LION	1	Whidbey Island	WA	WIC050503SD	03NWR05002	M	236	WSU/Island County Beachwatchers
5/4/2003	HARBOR PORPOISE	1	Sequim	WA	DNG-03-002	03NWR05003	F	200	USFWS
5/4/2003	HARBOR PORPOISE	1	Sequim	WA	DNG-03-003	03NWR05004	U	84	USFWS
5/4/2003	HARBOR PORPOISE	1	San Juan Island	WA	2003-SJ007	03NWR05005	F	126	Whale Museum
5/5/2003	HARBOR PORPOISE	1	San Juan Island	WA	2003-SJ008	03NWR05006	F	152	Whale Museum
5/6/2003	HARBOR PORPOISE	1	Sequim	WA	DNG-03-001	03NWR05007	F	146	USFWS
5/9/2003	HARBOR PORPOISE	1	Port Angeles	WA	OCNMS03Pp01	03NWR05008	M	146	Olympic Coast National Marine Sanctuary
5/11/2003	UNSPECIFIED SEA LION	1	Point No Point	WA	03-KP-017	03NWR05009	U	N/E	Public
5/12/2003	HARBOR PORPOISE	1	Ocean City	WA	03-GH-159	03NWR05034	U	N/E	Cascadia Research Collective
5/12/2003	HARBOR PORPOISE	1	Whidbey Island	WA	03-IS-160	03NWR05033	U	N/E	WSU/Island County Beachwatchers
5/13/2003	HARBOR PORPOISE	1	Whidbey Island	WA	WIC051303SD	03NWR05010	M	160	WSU/Island County Beachwatchers
5/14/2003	DALL'S PORPOISE	1	Fidalgo Island	WA	03-SK-161	03NWR05035	U	N/E	Public/Whale Museum
5/16/2003	HARBOR PORPOISE	1	Port Angeles	WA	OCNMS03Pp02	03NWR05011	F	141	Olympic Coast National Marine Sanctuary
5/17/2003	HARBOR PORPOISE	1	Whidbey Island	WA	WIE051703SB	03NWR05019	F	137	WSU/Island County Beachwatchers
5/20/2003	HARBOR PORPOISE	1	San Juan Island	WA	2003-SJ009	03NWR05012	M	123	Whale Museum
5/22/2003	HARBOR SEAL	1	Ruby Beach	WA	03-JE-018	03NWR05013	U	N/E	National Park Service
5/27/2003	CALIFORNIA SEA LION	1	Whidbey Island	WA	03-IS-019	03NWR03014	U	N/E	Public
5/31/2003	HARBOR SEAL	1	Birch Bay	WA	03-WH-022	03NWR05017	U	112	Public
5/31/2003	NORTHERN ELEPHANT SEAL	1	Forks/Kalaloch	WA	03-JE-021	03NWR05016	U	320	National Park Service
6/2/2003	HARBOR PORPOISE	1	Long Beach	WA	CRC-490	03NWR06005	M	141	Cascadia Research Collective
6/12/2003	HARBOR SEAL	1	Blaine	WA	03-WH-064	03NWR06014	M	84	
6/13/2003	HARBOR SEAL	1	Moclips	WA	03-GH-024	03NWR06002	U	61	Public
6/16/2003	HARBOR SEAL	1	Copalis	WA	03-GH-025	03NWR06003	U	N/E	Public
6/16/2003	UNSPECIFIED TOOTHED WHALE	1	Ocean Shores	WA	03-GH-027	03NWR06004	U	152	Public
6/17/2003	HARBOR SEAL	1	Lummi Island	WA	03-WH-072	03NWR06019	M	74	

Appendix F. Summary of post mortem findings in harbor porpoises stranded in Washington State 2 May – 2 June 2003

Field Number	03NWR05001	03NWR05005	03NWR05006	03NWR05007	03NWR05008	03NWR05010	03NWR05011	03NWR05012	03NWR05019	03NWR06005
Findings										
Human interaction						MC*	MC*			
Emaciation					+ IF	+ IF				+++ MC
Fractures										
Occipital bone						++ MC				
Cranium							++++ LC			
Inner ears										
Intracochlear hemorr.				+ IF			++ MC			
Peribullar hemorrhage	++ IF	+ IF	++ MC		+ IF	+ IF		++ MC		+++ MC
Salmonellosis			++ LC							
Spinal cord										
Clot formation	+ IF	++ IF			+ IF		+ IF	++ IF		
Skin										
Diatoms				+ IF				+ IF		
Lung										
Pneumonia										++++ LC
Colon										
Hypertrophy										++++ MC
Abdominal Cavity										
Peritonitis/serositis			+ MC		++ MC					
Epididymis										
Abscess					+ IF					
Parasites										
Lung worm	+ IF	+ IF	++ IF	+ IF	++ IF	+ IF	+ IF	+ IF	++ IF	+++ MC
Biliary	+ IF	++ IF	+ IF	++ IF	++ IF	+ IF	++ IF	++ IF	++ IF	++ IF
Subcutaneous				+ IF	++ IF			++ IF		+++ IF
Gastrointestinal		+ IF	+++ IF					+ IF		+++ IF
Peribullar	/+ F	+ IF			++/+ IF	++/+ IF	++/+ IF	+++ /+++ (MC)	++ /++ IF	+++ /+++ IF
Intracranial								+++ (MC)		

Legend: Severity of condition
 + mild
 ++ moderate
 +++ marked
 ++++ severe

Contribution to death of animal
 LC Likely the cause of death
 MC May be the cause of death/May have contributed to death
 IF Incidental finding (not linked to cause of death)
 * Speculative - could be due to predation.

left/right side of animal